

## REPLICATION OF A BOVINE CORONAVIRUS IN ORGAN CULTURES OF FOETAL TRACHEA

E.J. STOTT, L.H. THOMAS, J.C. BRIDGER and N.J. JEBBETT

*Agricultural Research Council, Institute for Research on Animal Diseases, Compton, Near Newbury, Berkshire (Great Britain)*

(Received 26 July 1976)

### ABSTRACT

Stott, E.J., Thomas, L.H., Bridger, J.C. and Jebbett, N.J., 1976. Replication of a bovine coronavirus in organ cultures of foetal trachea. *Vet. Microbiol.*, 1: 65-69.

A strain of bovine coronavirus (BC) adapted to tissue culture, was inoculated into organ cultures of bovine foetal trachea. Haemagglutinin in the fluid from infected organ cultures reached titres of 32 and characteristic coronavirus particles were observed electron microscopically. BC virus antigen was detected in frozen sections of the organ cultures by staining with fluorescent antibody. These data were evidence that BC virus replicated in organ cultures of respiratory tissue. The use of this technique for primary isolation of bovine coronaviruses from field material is discussed.

### INTRODUCTION

Most coronaviruses so far described have two significant biological characteristics. First, they have a marked tropism for either the respiratory or enteric tract and secondly, they are difficult to isolate in cell culture.

The bovine coronavirus (BC virus) is associated with neonatal diarrhoea (Stair et al., 1972), and thus resembles the virus of transmissible gastroenteritis (TGE) of swine and a recently reported human virus (Caul and Clarke, 1975). In contrast, avian infectious bronchitis virus (Cunningham, 1966), the rat coronavirus (Parker et al., 1970) and most coronaviruses of man (Bradburne and Tyrrell, 1971) are associated with respiratory disease. However, recent reports (Underdahl et al., 1974; Kemeny et al., 1975) indicate that TGE virus infection has a respiratory phase. Therefore, it is possible that BC virus might replicate in respiratory tissue.

The bovine coronavirus was originally characterised by animal passage after purification from faeces (Stair et al., 1972). Later it was grown in cell culture with difficulty (Mebus et al., 1973a). Since inoculation of organ cultures of foetal trachea (Hoorn and Tyrrell, 1969) has proved to be a sensitive technique for detecting human respiratory coronaviruses (Bradburne and

Tyrrell, 1971), it is possible that a similar technique could be used for the detection of bovine coronaviruses.

In this paper, inoculation of organ cultures of bovine foetal trachea with bovine coronavirus is described. The affinity and pathogenicity of this virus for respiratory tissue is discussed and the use of this technique for the isolation of coronavirus from field material is suggested.

#### MATERIAL AND METHODS

*Virus.* — The American strain of bovine coronavirus, BC-1 (Stair et al., 1972) was kindly supplied by Dr. C.A. Mebus. It had been passed over 20 times in bovine kidney cells.

*Organ cultures.* — Tracheal organ cultures from four bovine foetuses between 5 and 6 months of gestation were prepared as described by Thomas and Howard (1974). They were maintained as rings in rolled tubes at 37°C in Eagle's basal medium containing 0.14% sodium bicarbonate, 0.09% bovine plasma albumin (Armour Pharmaceutical Co. Ltd), 5% tryptose phosphate broth, 100 units/ml penicillin, 100 µg/ml streptomycin, 250 µg/ml ampicillin, 100 µg/ml kanamycin, 25 µg/ml mycostatin and 30 mM HEPES buffer adjusted to pH 7.2 with 1 N NaOH. Cultures were inoculated with 0.2 ml of virus and after incubation for 2 h at 37°C, cultures were washed three times to remove unadsorbed virus. Thereafter medium was changed and samples taken every 3 or 4 days.

*Haemagglutination tests.* — Rat erythrocytes were washed three times in 0.85% NaCl and resuspended at 1% in phosphate buffered saline containing 0.1% bovine plasma albumin. Haemagglutinin was titrated in microtitre plates and the cells allowed to settle for 2 h at room temperature.

*Fluorescent antibody staining.* — Rings of tracheal organ cultures were frozen in liquid nitrogen and sectioned in a cryostat. The frozen sections were stained using a directly conjugated (F.I.T.C.) antiserum against BC-1 kindly supplied by Dr. A.M. Delvaux, of R.I.T., Rixensart, Belgium. The antiserum was absorbed with uninoculated tracheal rings before use.

*Histology.* — Pieces of tracheal tissue were fixed in Bouins solution, embedded in paraffin wax and serial sections cut and stained by haematoxylin/eosin and Lendrum's phloxine tartrazine method.

*Electron microscopy.* — Twenty ml of medium harvested from organ cultures was frozen, thawed and clarified by centrifugation at 8 000 g for 30 min. The supernatant fluid was then centrifuged at 100 000 g for 1 h, the pellet resuspended in 25 ml phosphate buffered saline and centrifuged again at the same speed. The pellet of material was resuspended in a few drops of

phosphate buffered saline and a drop was placed on an electron microscope grid (for about 30 sec) stained with 2% (w/v) phosphotungstic acid, pH 6.0, and examined in a Phillips 300 electron microscope at 80 kV.

## RESULTS

Bovine coronavirus, BC-1, replicated in organ cultures from each of four different foetuses. Maximum titres of haemagglutinin were detected between 10 and 14 days after inoculation. The virus was passed serially three times in organ cultures. The medium collected when haemagglutinin titres were highest was used and 0.1 ml was inoculated undiluted into fresh cultures. Maximum haemagglutinin titres increased from 4 in the first passage to 32 in the third (Table I). No haemagglutinin was detected in uninoculated organ cultures from any of the foetuses.

TABLE I

Haemagglutinin titres in organ cultures inoculated with BC-1 virus

Organ culture passage	Day after inoculation						
	0	3	7	10	14	17	21
1	0	0	0	2	4	4	ND
2	0	0	4	8	16	16	16
3	0	0	4	32	32	16	16

Although some ciliary damage was detected in the first passage of BC-1 virus, this was not seen in subsequent passages and could not be correlated with virus replication.

No histological changes were seen in either infected or control cultures. A confluent columnar, ciliated epithelium was present up to 21 days after inoculation. No inclusion bodies were seen in infected cultures.

Viral antigen stained with fluorescent antibody was first detected 7 days after inoculation in the cytoplasm of the glandular epithelium of the lamina propria. By 14 days after inoculation patchy cytoplasmic fluorescence was also seen in the ciliated epithelium. Maximum fluorescence was seen 21 days after inoculation in both the lamina propria and epithelium when less than 20% cells showed fluorescence. Patchy fluorescence of the peritracheal connective tissue was also seen 21 days after inoculation.

Examination of material from passages 2 and 3 in the electron microscope revealed particles with characteristic coronavirus morphology ranging in diameter from 110 nm to 150 nm (Fig. 1). Many particles had a complete ring of club-like projections which were 17 to 24 nm long.

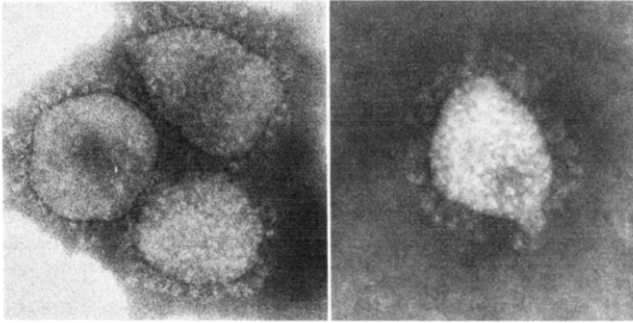


Fig. 1. Negatively stained coronavirus particles from organ culture fluid ( $\times 190\,000$ ).

## DISCUSSION

The bovine coronavirus replicated in organ cultures of bovine foetal trachea. Evidence of multiplication included demonstration of increasing titres of haemagglutinin, appearance of characteristic particles and direct staining of antigen by fluorescent antibody specific for BC-1 virus. Although the virus had been adapted to cell culture, its growth in organ cultures of trachea has not previously been described and raises important questions. First, does BC virus infect the respiratory tract *in vivo*? Secondly, do organ cultures provide a practical technique for the primary isolation of bovine coronaviruses?

Growth of a virus in respiratory epithelium *in vitro* is not evidence that similar growth occurs *in vivo*. Mebus et al. (1973b) have studied the pathology of BC virus infection in gnotobiotic calves. Although they found enlarged cells in the alveolar walls of the lung, no BC virus antigen was detected by immunofluorescent staining of sections. There is, therefore, no evidence so far that BC virus infects the respiratory tract *in vivo*.

Diagnosis of coronavirus infection by ultracentrifugation followed by electron microscopy requires access to expensive equipment. However, provided the sample contains large numbers of virus particles, they can be rapidly identified. On the other hand, inoculation of organ cultures of trachea with faecal material followed by titration of haemagglutinin requires little equipment and should detect small amounts of infectious virus. Furthermore, a coronavirus isolated in this way may be typed serologically by haemagglutination-inhibition tests or immunofluorescent staining of sections of infected organ cultures. The relative efficiency of the two methods of diagnosis is currently under investigation.

## ACKNOWLEDGEMENTS

We thank Mr. L.J. Richardson, Meat Inspector at the Swindon abattoir of Thos. Borthwick & Sons, for the supply of fetuses.

## REFERENCES

- Bradburne, A.F. and Tyrrell, D.A.J., 1971. Coronaviruses of man. *Prog. Med. Virol.*, 13: 373—403.
- Caul, E.O. and Clarke, S.K.R., 1975. Coronavirus propagated from a patient with non-bacterial gastroenteritis. *Lancet*, ii: 953—954.
- Cunningham, C.H., 1966. Newer information on the properties of infectious bronchitis virus. *Proc. 12th World Poultr. Congr.*, pp. 416—418.
- Hoorn, B. and Tyrrell, D.A.J., 1969. Organ cultures in Virology. *Prog. Med. Virol.* 11: 408—450.
- Kemeny, L.J., Wiltsey, V.L. and Riley, J.L., 1975. Upper respiratory infection of lactating sows with transmissible gastroenteritis virus following contact exposure to infected piglets. *Cornell Vet.*, 65: 352—362.
- Mebus, C.A., Stair, E.L., Rhodes, M.B. and Twiehaus, M.J., 1973a. Neonatal calf diarrhoea: Propagation attenuation and characteristics of a coronavirus-like agent. *Am. J. Vet. Res.*, 34: 145—150.
- Mebus, C.A., Stair, E.L., Rhodes, M.B. and Twiehaus, M.J., 1973b. Pathology of neonatal calf diarrhoea induced by a coronavirus-like agent. *Vet. Pathol.*, 10: 45—64.
- Parker, J.C., Cross, S.S. and Rowe, W.P., 1970. Rat coronavirus (RCV): a prevalent, naturally occurring pneumotropic virus of rats. *Arch. Gesamte Virusforsch.*, 31: 293—302.
- Stair, E.L., Rhodes, M.B., White, R.G. and Mebus, C.A., 1972. Neonatal calf diarrhoea: Purification and electron microscopy of a coronavirus-like agent. *Am. J. Vet. Res.*, 33: 1147—1156.
- Thomas, L.H. and Howard, C.J., 1974. Effect of *Mycoplasma dispar*, *Mycoplasma bovirhinis*, *Acholeplasma laidlawii* and T-mycoplasmas on explant cultures of bovine trachea. *J. Comp. Pathol.*, 84: 193—201.
- Underdahl, N.R., Mebus, C.A., Stair, E.L., Rhodes, M.B., McGill, L.D. and Twiehaus, M.J., 1974. Isolation of transmissible gastroenteritis (TGE) virus from lungs of market swine. *Am. J. Vet. Res.*, 35: 1209—1216.