

## Letters to the Editor

## Enzyme activity (u/l)

Day after first admission	AST (37°C) Upper reference limit	HBD (25°C)	Creatine kinase (37°C)	CK-B (37°C)	CK-B/CK %
42		140	170	6	3
1	59				
2	84	332	413	105	25
3	68	437	366		
4	63	526			
8	36	438	64		

AST = serum aspartate transferase activity; HBD =  $\alpha$ -hydroxybutyrate dehydrogenase; CK = creatine kinase; CK-B = creatine kinase B subunit activity.

CK-BB, CK-MB was absent.

She was discharged from hospital three weeks after admission. Subsequently she experienced pains in both legs, limb weakness, and exhibited weight loss, anorexia, and general malaise. She was readmitted to hospital 18 days after discharge. Her liver was enlarged two to three finger breadths below the costal margin and a scan of the liver showed that there were cold areas in keeping with secondary carcinoma. Creatine kinase remained normal but  $\alpha$ -hydroxybutyrate dehydrogenase was now increased to about three times the upper limit of normal. She deteriorated rapidly and died six days after readmission. Necropsy showed an oat cell carcinoma of bronchus with metastatic tumour deposits throughout the liver substance. There was no evidence of myocardial infarction or fibrosis, although there was coronary artery atheroma.

Increased serum lactate dehydrogenase (LD) activity is found in about one third of patients with malignant disease. The increases are greater and more common when the disease is widespread. The electrophoretic pattern shows an increase in the more cathodic isoenzymes, particularly LD 3, 4, and 5.<sup>3</sup> Serum  $\alpha$ -hydroxybutyrate dehydrogenase activity is occasionally also increased. Although the determination preferentially measures LD<sub>1</sub>, it is not specific to this fraction.

The presence of brain type creatine kinase<sup>2</sup> has been observed in patients with disseminated malignancy arising from a primary bronchial carcinoma. Spooner *et al*<sup>4</sup> postulated that bleeding into a tumour deposit may release brain type creatine kinase from the metastasis into plasma. The combination of serial enzyme changes initially led to diagnostic confusion. This was further compounded by the finding of

an increase in CK-B subunit activity.

Only when creatine kinase isoenzyme electrophoresis failed, to show the MB isoenzyme and confirmed the presence of the BB isoenzyme could myocardial infarction be excluded biochemically. This illustrates the importance of confirming B subunit increase by a technique specific for CK-MB, particularly when the percentage CK-B subunit activity in serum is high (greater than 12%, apparent CK-MB greater than 25%).<sup>5</sup>

## References

- 1 Cleve HJW, Tua DC. Studies of the Regan alkaline phosphatase isoenzyme in plasma from a lung-carcinoma patient. *Clin Chem* 1983;29:715-17.
- 2 Coolen RB, Pragey DA, Nosanchuk JS, Bleding R. Elevation of brain-type creatine kinase in serum from patients with carcinoma. *Cancer* 1979;44:1414-8.
- 3 Moss DW. *Isoenzymes*, 1st ed. London: Chapman and Hall, 1982:163.
- 4 Spooner RJ, McKenna JP, Borland WW. Changes in serum creatine kinase BB activity in a patient with chest pain. *Clin Chem* 1984;30:1105-6.
- 5 Stein M, Bohner J, Steinhart R, Eggstein M. Macro creatine kinase: determination and differentiation of two types by their activation energies. *Clin Chem* 1982; 28:19-24.

DF DAVIDSON,\*  
O MVANTEMBE,†  
A GUNNEBERG†

\*Department of Biochemistry,  
Crosshouse Hospital,  
Kilmarnock,  
Scotland KA2 0BE

†Department of General Medicine,  
Heathfield Hospital,  
Ayr, Scotland LA8 9DZ

## Enteric coronavirus in symptomless homosexuals

In January 1984 we started a small prospective study of enteric pathogens in male homosexuals attending a genitourinary medicine clinic. At their first attendance patients seen by one of us (MNB) and admitting to be homosexuals were asked to submit a stool sample to the laboratory.

Stool specimens were cultured for salmonellas, shigellas, and campylobacters using standard methods and were examined for parasites by light microscopy on direct preparations and after formol-ether concentration. Heat fixed faecal smears were examined for *Cryptosporidium* using a phenol-auramine stain. Where sufficient material was available, stools were prepared<sup>1</sup> and examined for viruses by electron microscopy.

About 25% of patients submitted specimens as requested. The table shows the results. These confirm the prevalence of enteric parasites previously reported in homosexuals.<sup>2</sup> The most striking finding of the survey, however, was the identification of coronaviruses by electron microscopy in eight of 23 (35%) of specimens (figure). By contrast, of 96 samples routinely submitted to the laboratory over the period of study from adult males aged between 18 and 50, only one was positive for coronavirus. This patient was a homosexual who was subsequently diagnosed as having acquired immune deficiency syndrome (AIDS).

Coronaviruses are well known to be causative agents of respiratory disease.<sup>3</sup> In addition, enteric coronaviruses have been associated with some outbreaks of gastroenteritis and malabsorption.<sup>4,5</sup> Enteric coronaviruses, however, have also been found in institutionalised patients without overt signs of illness, and their excretion may be protracted lasting up to several years.<sup>5</sup> In the general population the pathological importance of excretion of enteric coronaviruses is not understood but may be indicative of poor hygienic standards.

The prevalence of enteric coronaviruses in male homosexuals in our study is very striking, and it is interesting that a recent study by Kern in Germany<sup>6</sup> showed that 50% of patients with AIDS were excreting enteric coronaviruses whereas no virus particles were found in 18 control homosexuals.

Although sera are available from our patients, we have not felt ethically justified in retrospectively testing them for HIV antibody without their consent. It would be

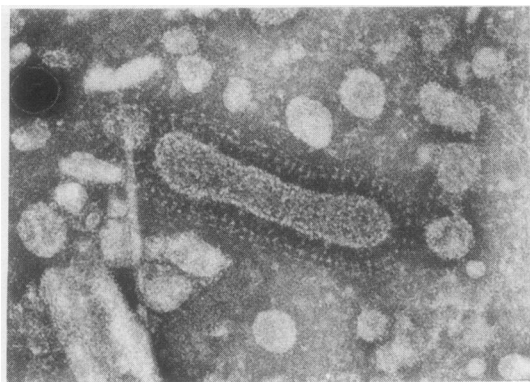


Figure Faecal coronavirus from male homosexual.  $\times 150\,000$ .

#### Microbiological results on stool samples

##### Organism

<i>Salmonella</i> sp	0
<i>Shigella</i> sp	0
<i>Campylobacter</i> sp	3
<i>Giardia lamblia</i>	2
<i>Entamoeba histolytica</i>	1
<i>Entamoeba coli</i>	2
<i>Endolimax nana</i>	1
<i>Iodamoeba butschlii</i>	2
<i>Cryptosporidium</i>	0
Small round featureless virus	2
Coronavirus	8*
Total No of patients	33

\*Electron microscopy was performed on only 22/23 specimens.

speculative at present to suggest any correlation between the finding of coronaviruses in homosexuals and either HIV infection or AIDS. We intend to amplify our study and to try to determine the importance of excretion of enteric coronaviruses in this group of patients.

#### References

- Riordan T, Craske J, Roberts JL, Curry A. Food borne infection by a Norwalk like virus (small round structured virus). *J Clin Pathol* 1984;37:817-20.
- Quinn TC, Walter E, Stamm MD, et al. The polymicrobial origin of intestinal infection in homosexual men. *New Engl J Med* 1983;309:576-82.
- Tyrrell DAJ, Almeida JD, Cunningham CH, et al. Coronaviridae. *Intervirology* 1975; 5:76-82.
- Caul EO, Paver WK, Clarke SKR. Coronavirus particles in faeces from patients with gastroenteritis. *Lancet* 1975;i:1192.
- Mathan M, Mathan VI, Swaminathan SP, et al. Pleomorphic virus-like particles in human faeces. *Lancet* 1975;i:1068-9.

6 Kern P, Müller G, Schmitz H, et al. Coronavirus-like particles in homosexual men. *Klin Wochenschr* 1985;63:68-72.

T RIORDAN,\*

A CURRY,\*

MN BHATTACHARYYA†

\*Public Health Laboratory Service,  
Withington Hospital,  
Manchester M20 8LR

†Department of Genitourinary Medicine,  
Manchester Royal Infirmary,  
Oxford Road,  
Manchester M13 9NL

#### Hepatitis A: a Kupffer cell disease?

Endotoxin values in peripheral blood and the titre of antibodies to enteric bacteria can be used as indices of Kupffer cell integrity.<sup>1</sup> In human hepatitis A virus infection

endotoxin in the serum is found more often than in other types of viral hepatitis.<sup>2</sup> The pyrogenic response induced by the endotoxin most probably explains why fever is a more common finding in human hepatitis A virus infection than in hepatitis B virus or hepatitis non-A, non-B virus infections.<sup>2</sup> Moreover, the striking increase in serum IgM values, again characteristic of human hepatitis A virus infection, is not only the result of an increased production of IgM against hepatitis A virus but also reflects a non-specific increase in IgM, in part directed against enteric bacteria.<sup>3</sup> Consequently, a dysfunction of the Kupffer cells in human hepatitis A virus infection has been postulated.<sup>2,3</sup>

We had the opportunity to look for morphological evidence supporting this hypothesis. We received fresh unfixed liver tissue from a patient with serologically confirmed acute hepatitis A virus infection taken three days after the onset of jaundice.

Routine histology showed portal and periportal inflammation with concomitant acinar zone I necrosis. Using monoclonal anti-hepatitis A virus antibodies, generously donated by Dr A MacGregor (Commonwealth Serum Laboratories, Australia),<sup>4</sup> a granular immunoreactivity was observed in the macrophages bordering the inflammatory infiltrate and located in zone I of the parenchyma. Hepatitis A virus antigens were absent in hepatocytes. On electron microscopy, empty and full particles, as previously described in hepatitis A virus infection,<sup>5,6</sup> were noted in secondary lysosomes of large macrophages. In spite of extensive search no such structures could be identified in the surrounding liver cells. On immunoelectron microscopy, however, hepatitis A virus antigens were shown on the membranes of the rough endoplasmic reticulum in some hepatocytes.

In view of these findings we propose that the presence of particles like hepatitis A virus in zone I macrophages, resulting from either the phagocytic function of these cells or from their primary infection, causes the clearance dysfunction of Kupffer cells and hence is responsible for the clinical and biochemical findings in human hepatitis A virus infection mentioned here.

R SCIOT

R DE VOS

C DE WOLF-PEETERS

VJ DESMET

University Hospital St Rafaël,  
Laboratory for Histochemistry and

Cytochemistry,

Catholic University of Leuven,  
Leuven, Belgium



# Enteric coronavirus in symptomless homosexuals.

T Riordan, A Curry and M N Bhattacharyya

*J Clin Pathol* 1986 39: 1159-1160

doi: 10.1136/jcp.39.10.1159

---

Updated information and services can be found at:  
<http://jcp.bmj.com/content/39/10/1159.citation>

---

## Email alerting service

*These include:*

Receive free email alerts when new articles cite this article. Sign up in the box at the top right corner of the online article.

---

## Notes

---

To request permissions go to:  
<http://group.bmj.com/group/rights-licensing/permissions>

To order reprints go to:  
<http://journals.bmj.com/cgi/reprintform>

To subscribe to BMJ go to:  
<http://group.bmj.com/subscribe/>