

Pathogenicity and Antigen Detection of the Nouzilly Strain of Transmissible Gastroenteritis Coronavirus, in 1-Week-Old Piglets

M. J. Cubero, S. Bernard*, L. Leon, P. Berthon* and A. Contreras

*Facultad de Veterinaria, Departamento de Patología Animal, 30010 Murcia, España and *INRA, laboratoire de Pathologie Infectieuse et Immunologie, 37380 Nouzilly, France*

Summary

We compared the pathogenicity and the sites of multiplication of the attenuated Nouzilly strain, with the highly passaged Purdue-115 and the virulent Gep II strains of transmissible gastroenteritis (TGE) coronavirus, in 1-week-old weaned piglets. The immunohistochemical peroxidase technique, with an antiviral nucleoprotein monoclonal antibody, was used for the localization of the multiplication sites, in the intestine and other organs. The Gep II and the Purdue-115 strains, administered orally to piglets, caused clinical signs and lesions of TGE. These strains multiplied within the intestinal tract in the enterocytes of the jejunum and ileum, Peyer's patches and mesenteric lymph nodes. In view of the small numbers of infected cells in the tonsils, spleen, kidney, liver and lung, these tissues are not considered to be preferential multiplication sites. The attenuated Nouzilly strain multiplies only in the ileum and the mesenteric lymph nodes. The variation in the tropism for particular parts of the intestine (with the preferential localization of the virus in the ileum rather than the jejunum), could be related to the high degree of attenuation of the Nouzilly strain.

Introduction

Transmissible gastroenteritis (TGE) is a highly contagious, enteric disease of swine characterized by vomiting, severe diarrhoea and a high mortality rate among piglets under 2 weeks of age. TGE is one of the most devastating diseases in new-born pigs because of high mortality, the lack of response to treatment and the limited efficiency of available vaccines (Bohl, Gupta, Olquin and Saif, 1972; Bohl, 1989; Moxley and Olson, 1989).

Detection of TGE viral antigens within the infected enterocytes from the small intestine is probably the simplest, the most rapid and the most reliable method for diagnosing TGE in piglets. The best results are obtained from piglets killed at a very early stage of disease, since the infected cells are rapidly shed from the villi. Frozen tissue sections from the jejunum and the ileum are examined by direct or indirect immunofluorescence assays (Pensaert, Haelterman and Burnstein, 1970b; Motovski, Belopopska, Surtmadzhiev, Aleksieva

and Aleksandrov, 1985) and the immunoperoxidase test (Chu, Glock and Ross, 1982). An inverse correlation has been observed between the degree of TGE virus attenuation and the extension and the intensity of the intestinal infection (Hess, Bachmann and Hänichen, 1977), especially in the middle portion of the jejunum (Bachmann and Hess, 1978).

The degree of virus multiplication in the body of animals is of considerable value as an indication of the virulence of TGE virus (Furuuchi, Shimizu and Kumagai, 1975). Frederick, Bohl and Cross (1976) revealed the residual virulence for piglets of the attenuated Purdue-115 strain. On the other hand the Nouzilly strain, a possible candidate for an oral TGE virus vaccine, is non-pathogenic (Aynaoud, Nguyen, Bottreau, Brun and Vannier, 1985; Aynaoud, Bernard, Bottreau, Lantier, Salmon and Vannier, 1991). It is not known whether the two strains have other intense multiplication sites as well as enterocytes, when infecting both piglets and adult pigs.

The purpose of the present comparative study was to determine the effects of the attenuated Nouzilly strain of TGE virus, in TGE-susceptible 1-week-old piglets, and to map the virus distribution in tissues by an immunohistochemical technique. The clinical signs of the viral infection, the sites of viral multiplication and the intestinal lesions produced by this virus were compared with those seen in pigs exposed to the highly passaged Purdue-115 and the fully virulent Gep II strains of TGE coronavirus.

Materials and Methods

Animals

Four groups each of two 1-week-old Mei Shan piglets, previously weaned for 3 days, and fed with sterilized cows' milk, were bred in individual isolated units.

Virus

Three strains of transmissible gastroenteritis coronavirus were used: Nouzilly, an attenuated mutant obtained by a survivor selection process in the gastric juice of adult pigs (Aynaoud *et al.*, 1985); Purdue-115, a highly passaged TGE strain (Bohl *et al.*, 1972) cultured in RPD cells (pig kidney cell line) and the fully virulent Gep II strain of TGE (Aynaoud *et al.*, 1991). The virus suspensions of the Nouzilly and Purdue-115 strain were harvested at the first sign of a cytopathic effect (about 15 h post-infection) and stored at -70°C . A virulent virus stock suspension (about 10^6 LD₅₀ per ml) was prepared from the contents of the small intestine of colostrum-deprived new-born piglets that had been infected with the Gep II strain.

Experimental Infection

Two groups were orally infected with 10^8 p.f.u. in 2 ml of MacIlvaine buffer (0.025M, pH 4) of the Nouzilly (Group I) and the Purdue-115 (Group II) strains, respectively; the incubation period in both groups was 72 h. Group III received, by mouth, 10^4 LD₅₀ of the Gep II strain and the piglets were killed 22 h post-infection. The control group (Group IV) received a placebo of MacIlvaine buffer, and the animals were killed 22 h later.

Collection of Specimens

After necropsy, samples were taken from the tongue, tonsils, lung, liver, kidney, spleen, middle zones of the gut, duodenum, jejunum, ileum and colon and one from each mesenteric and inguinal lymph node. The intestine was rapidly washed with physiological buffer and collected for antigen detection. The intestine was filled with Tissue-Teck (Miles) and tissues were frozen immediately in liquid nitrogen and stored at -70°C until use. The frozen specimens were cross-sectioned with a cryostat-microtome at -20°C . Sections $5\ \mu\text{m}$ in thickness were positioned on gelatine-coated glass slides, fixed with acetone (-20°C) for 20 min and stored at -70°C .

Monoclonal Antibodies

Monoclonal antibodies (mAbs) previously described (Laude, Chapsal, Gelfi, Labiau and Grosclaude, 1986) were used against the three major structural proteins of transmissible gastroenteritis virus, the envelope protein (M, n°25-22), the peplomer protein (S, n°51-13) and the nucleoprotein (N, n°22-6).

Immunoperoxidase Technique

The histological sections were stained by the immunohistochemical peroxidase technique (Ingh, Bara, Cornelisse and Nap, 1987) and modified by (a) the use of the monoclonal antibody against the nucleoprotein from the Purdue-115 strain of TGE virus and (b) the detection of endogenous peroxidase by a solution of diaminobenzidine, cobalt chloride and hydrogen peroxide, giving rise to a dark stain, contrasting with the brown staining of the specific reaction. (Olivier, M., personal communication).

The acetone-fixed sections were washed three times for 5 min in 0.05 M phosphate buffered saline solution (pH 7.4). They were then stained according to the following procedure: (1) mAbs against nucleoprotein diluted 1:500 in PBS and 1 per cent BSA was placed on the specimens for 45 min; (2) tissue sections were treated in a staining chamber with freshly prepared 0.05 per cent diaminobenzidine, 0.005 per cent CoCl_2 , 0.005 per cent H_2O_2 solution for 20 min; (3) normal swine serum was placed on the specimens for 45 min; (4) tissue sections were treated with peroxidase-conjugated rabbit immunoglobulin (Ig) to mouse Ig (Dakopatts code P-161) previously diluted 1 in 40 in PBS and adsorbed in pig liver polymer, for 45 min; (5) peroxidase conjugated swine Ig to rabbit Ig (Dakopatts code P-217), previously diluted 1 in 40 in PBS and adsorbed in pig liver polymer, for 45 min; (6) tissue sections were treated in a staining chamber with freshly prepared 0.05 per cent diaminobenzidine, 0.005 per cent H_2O_2 solution for 20 min; (7) tissue sections were counterstained with Harris haematoxylin, dehydrated and covered with mounting medium (Eukitt) and cover glasses and examined with a light microscope. A control section in which the monoclonal antibody was substituted by PBS was always included.

All the procedures were carried out at room temperature in a dark, humid chamber. The slides were washed for 5 min with phosphate-buffered saline solution three times after each of steps 1 to 6 (except in between steps 3 and 4).

Immunocapture ELISA Technique

We used an immunocapture (sandwich) enzyme-linked immunosorbent assay (ELISA) with monoclonal and polyclonal antibodies (Bernard, Lantier, Laude and Aynaud, 1986) to detect transmissible gastroenteritis virus antigens in the intestinal contents.

Results

Clinical Signs and Lesions after Virus Inoculation

Table 1 shows the clinical and lesional pattern of TGE in piglets infected with the attenuated and virulent strains. The piglets of group I (Nouzilly) showed neither diarrhoea nor vomiting and the only macroscopic sign of the disease presented by these piglets was a moderate dehydration. Microscopically, compared to the marked shortening of the intestinal villi (1/1 Gep II strain and 3/1 Purdue-115 strain), we only noted a slight alteration of the villi (6/1) and leucocytic infiltration in the submucosa with the Nouzilly strain.

Table 1
Clinical signs and lesions in piglets after infection with Nouzilly, Purdue-115 and Gep II strains of TGE coronavirus or control

	<i>Piglet groups</i>			
	<i>Group I</i> (<i>Nouzilly</i>)	<i>Group II</i> (<i>Purdue-115</i>)	<i>Group III</i> (<i>GepII</i>)	<i>Group IV</i> (<i>Control</i>)
Clinical signs				
anorexia	yes	yes	yes	no
vomiting	no	yes (24 h)	yes (18 h)	no
diarrhoea	no	yes (48 h)	yes (20 h)	no
Macroscopic lesions				
dehydration	moderate	intense	intense	no
stomach	normal	full of milk		normal
intestine	normal	thinned walls mucosa congestion		normal
mesenteric	normal	congestive		normal
Microscopic lesions				
villous atrophy*	6/1	3/1	1/1	no
		necrosis, desquamation of enterocytes congestion and leucocytic infiltration		no

* villous height to crypt depth ratio.

Table 2
Amounts of TGE virus antigens in the contents of the gut segments. Viral antigens were detected by the immunocapture ELISA technique. Results are expressed as optical density (OD) means (two piglets). Background value 0.05

	<i>Piglet groups</i>			
	<i>Group I</i> (<i>Nouzilly</i>)	<i>Group II</i> (<i>Purdue-115</i>)	<i>Group III</i> (<i>Gep II</i>)	<i>Group IV</i> (<i>Control</i>)
Duodenum	0.061	0.112	0.115	0.065
Jejunum	0.162	0.286	0.251	0.051
Ileum	0.286	0.111	0.280	0.054
Colon	0.180	0.102	0.369	0.050

Viral Antigens in the Content of Gut Segments Detected by Immunocapture ELISA Technique

Table 2 shows the amounts (optical density, OD) of TGE virus antigens in the contents of intestinal portions, detected by means of the sandwich ELISA technique. The viral antigens were present in all the segments of the intestine in the piglets infected with the virulent strain, in the jejunum with the Purdue-115 strain and only in the ileum with the attenuated Nouzilly strain.

Viral Antigen Detection in Different Tissues by Immunohistochemical Technique

The specific positive reaction was characterized by the presence of many brown granules in the cytoplasm of the infected cells. Non-specific granules caused by endogenous peroxidase activity in the cytoplasm of eosinophils were stained black.

In the piglets infected with the attenuated Nouzilly strain, the anti-N immunoreaction was weak in enterocytes of the jejunum and moderate in the ileum. Compared with the other virus strains, intense labelling was found in the intestine (Fig. 1). No immune reaction was found in the duodenum (Table 3). The local detection of the viral antigens in the intestine was consistent with the quantity of antigens detected in the intestinal fluids.

In the cells of Peyer's patches, detection of the viral antigens was weak with the attenuated virus strains and moderate with the virulent strain. In contrast,

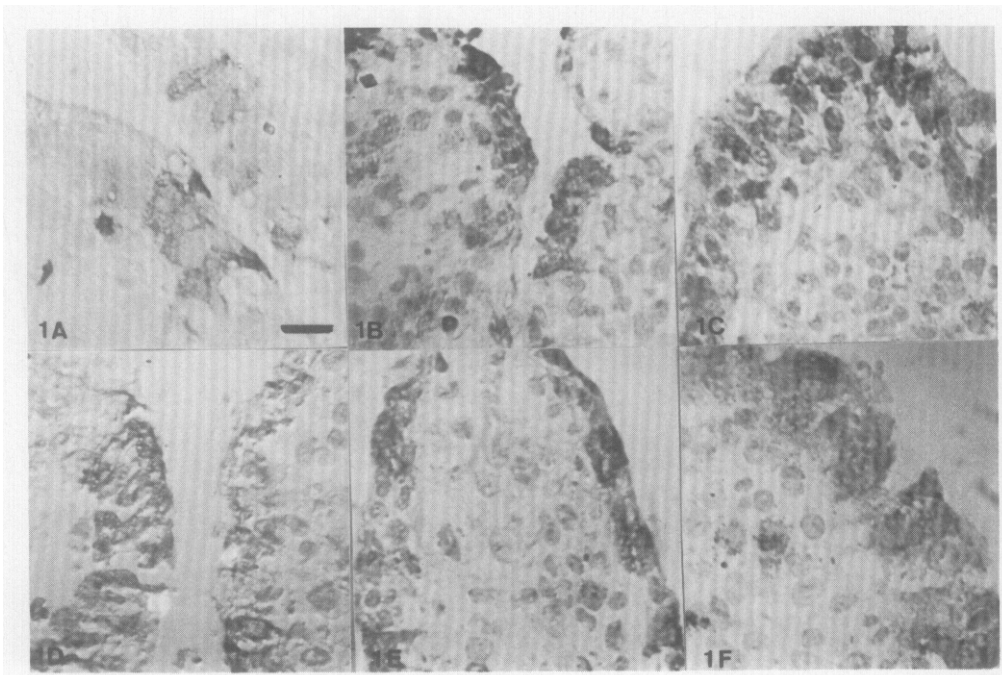


Fig. 1. Comparative distribution of the TGE coronavirus nucleoprotein antigens in the sections of jejunum (A, B, C) and ileum (D, E, F). One-week-old piglets were infected with attenuated Nouzilly (A, D), high passaged Purdue-115 (B, E) and virulent Gcp II (C, F). Bar = 25 μ m.

Table 3

Immunodetection of the TGE virus, with a monoclonal antibody specific to the viral nucleoprotein in the intestine of 1-week-old weaned piglets infected with the Nouzilly, Purdue 115 and Gep II strains of TGE virus. The intensity of the infection was estimated in numbers of infected enterocytes per microscopic field

	Piglet groups			
	Group I (Nouzilly)	Group II (Purdue-115)	Group III (Gep II)	Group IV (Control)
Duodenum	neg	neg	neg	neg
Jejunum	+	+++	+++	neg
Ileum	++	+++	+++	neg
Colon	neg	neg	neg	neg

neg (no positive enterocyte); + (weak immunoreaction: < 25 per cent positive enterocytes); ++ (moderate: 25 to 75 per cent positive enterocytes); +++ (intense: > 75 per cent positive enterocytes).

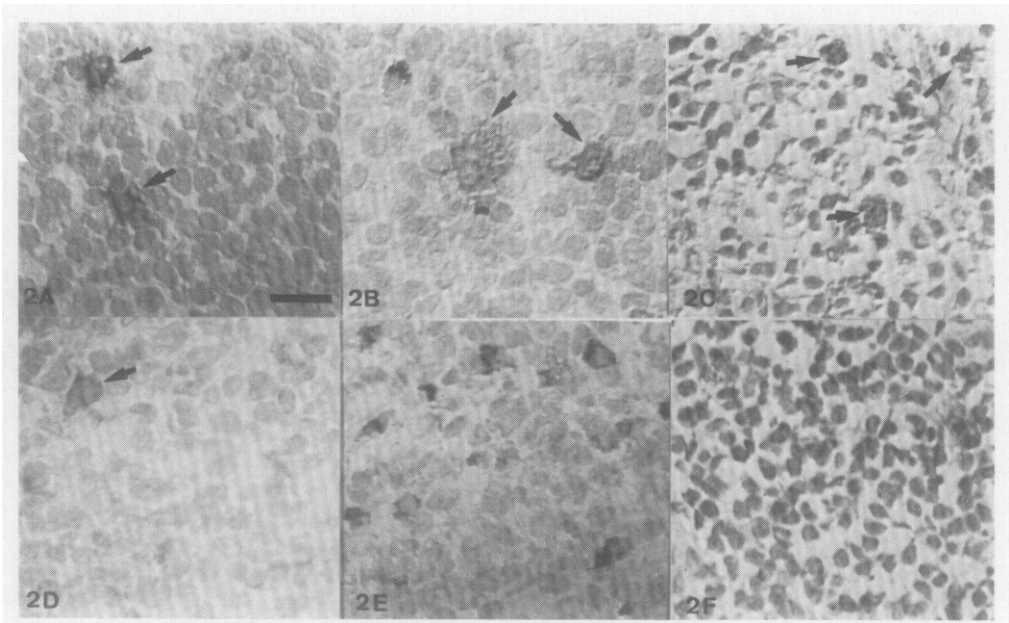


Fig. 2. Comparative distribution of the TGE coronavirus nucleoprotein antigens in the sections of mesenteric lymph node (A, B, C) and inguinal lymph node (D, E, F). One-week-old piglets were infected with attenuated Nouzilly (A, D), high passaged Purdue-115 (B, E) and virulent Gep II (C, F). Arrow = positive cell. Bar = 25 μ m.

the immune reaction in the macrophages and reticular cells from the mesenteric lymph node was strong for all the virus strains (Fig. 2, Table 4). In the tonsil cells and spleen, the immunodetection was weak and comparable for the three virus strains (Fig. 3, Table 4). The detection of the viral antigen in the other organs was negative for the piglets infected with the Nouzilly strain and weak for the other strains (Table 4).

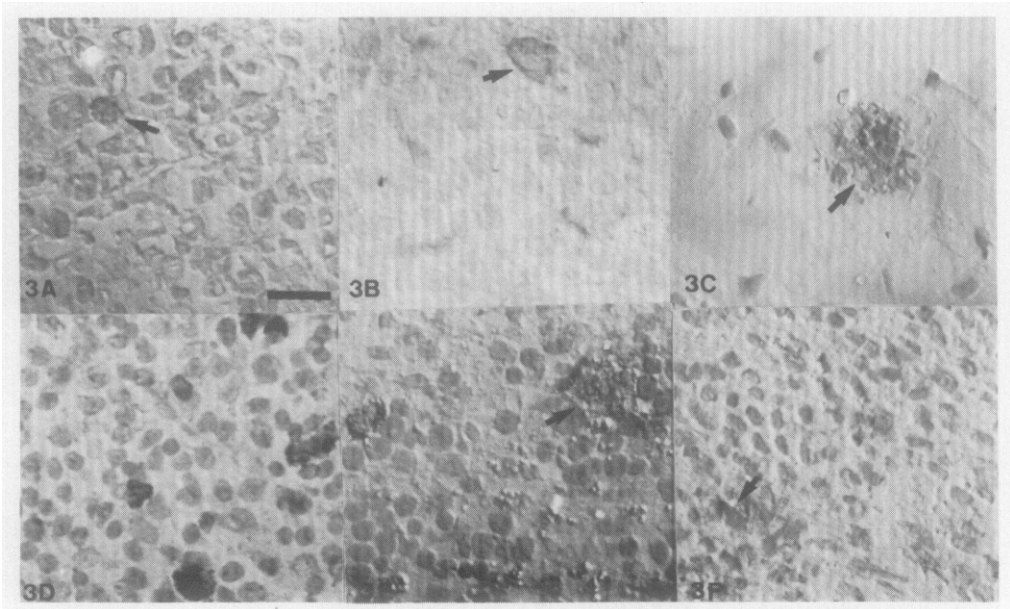


Fig. 3. Comparative distribution of the TGE coronavirus nucleoprotein antigens in the sections of tonsil (A, B, C) and spleen (D, E, F). One-week-old piglets were infected with attenuated Nouzilly (A, D), high passaged Purdue-115 (B, E) and virulent Gep II (C, F). Arrow = positive cell. Bar = 25 μ m.

Table 4

Immunodetection of the TGE virus, with a monoclonal antibody specific to the viral nucleoprotein in organs of 1-week-old weaned piglets infected with the Nouzilly, Purdue 115 and Gep II strains of TGE virus. The intensity of the infection was estimated in numbers of infected cells per surface section of organ

	Piglet groups			
	Group I (Nouzilly)	Group II (Purdue-115)	Group III (Gep II)	Group IV (Control)
Peyer's p. jejunum	+	+	++	neg
Peyer's p. ileum	+	+	++	neg
Mesenteric LN*	++	++	++	neg
Inguinal LN*	+	neg	neg	neg
Tongue	neg	neg	neg	neg
Tonsils	+	+	+	neg
Spleen	neg	+	+	neg
Liver	neg	+	neg	neg
Kidney	neg	+	+	neg
Lung	neg	neg	+	neg

* LN lymph nodes; neg (no positive cell per surface of section); + (weak immunoreaction: 1 to 20 positive cells per surface of section); ++ (moderate: >20 positive cells per surface of section).

Discussion

Clinical Signs

In the piglets inoculated with the Nouzilly strain, only anorexia and moderate dehydration were observed. Aynaud *et al.* (1985) showed that the Nouzilly strain was attenuated for new-born piglets. No death was observed even from doses of Nouzilly virus greater than 10^8 p.f.u. Delayed and mild diarrhoea only appeared on day 5 or 6 post-infection and lasted for 24 to 46 h. In contrast, a dose of 10^4 p.f.u. of Purdue-115 strain was sufficient to kill the piglets (Bernard, personal communication).

Both clinical signs and lesions induced in 1-week-old piglets by virulent Gep II and Purdue-115 strains were similar to classical descriptions (Bohl, 1989). These results are similar to those observed by others when comparing virulent and attenuated TGE strains (Frederick *et al.*, 1976; Pensaert, Burnstein and Haelterman, 1970a; Harada, Furuuchi, Kumagai and Sasahara, 1969; Bernard, personal communication).

Gross and Histopathological Lesions

The more obvious TGE lesion shown by histological examination was villous atrophy of the small intestine; intense (1/1) with the virulent strain, and moderate (3/1) in the caudal portion of the small intestine with the Purdue-115 strain. The attenuated Nouzilly strain causes a very light (6/1) villous atrophy. Consistent with this observation the *in vitro* replication of the Nouzilly strain is poor and delayed, compared with that of Purdue-115 (Aynaud *et al.*, 1985; Nguyen, Bernard, Bottreau, Lantier and Aynaud, 1987). The final infectivity titre of stock preparations of the Nouzilly strain is always 10 times lower than with the Purdue-115. Furuuchi *et al.* (1975) reported that less virulent isolates or attenuated TGE virus caused villous atrophy in the lower half of the small intestine, with little or no villous atrophy in the upper portion. This is in contrast to the virulent isolates which cause severe villous atrophy in nearly the whole length of the small intestine. The duodenum was usually not affected in TGE (Hooper and Haelterman, 1966) and villous atrophy was not observed (Moon, Norman and Lambert, 1973). Frederic (Frederic *et al.*, 1976), observed that the high-passaged Purdue-115 strain of TGE virus produced mild to moderate villous atrophy in the small intestine of new-born piglets but the high-passaged attenuated TO (Furuuchi *et al.*, 1979) and Nouzilly strains did not produce any change to the intestinal mucosa. These results, however, showed that the intensity of villous atrophy in the small intestine of pigs correlates with the degree of virulence of the TGE virus. This property might be of considerable value for evaluating the attenuation of TGE viral strains.

Moxley (Moxley and Olson, 1989), observed a partial protection manifested as a segmental distribution of villous atrophy in pigs suckling a sow previously infected or vaccinated with attenuated vaccine. Villous atrophy was primarily seen in the ileum instead of the jejunum. The multiplication of the virus in the distal portion of the intestine (ileum) was not important for the induction of

severe diarrhoea and a fatal outcome of this disease. The preferential site of multiplication of the Nouzilly strain in the ileum could be linked with the few clinical signs in piglets and the absence of mortality after viral infection.

TGE virus isolates have been reported to have a tropism, not only along the intestinal tract but also along the respiratory tract, without causing respiratory disorders (Kemeny, Wiltsey and Riley, 1975). Highly attenuated strains of TGE virus have also been reported to replicate in the upper respiratory tract and lung but not in the intestine of new-born pigs (Furuuchi *et al.*, 1975). However, piglets infected intranasally or orally with 10^4 TCID₅₀ Miller strain of TGEV developed, in addition to typical enteric lesions, dehydration and congestion of the mesenteric vessels, thymic atrophy, depletion of splenic periarteriolar sheaths, mild multifocal hepatic necrosis, mild rhinitis, moderate ulcerative laryngitis, multifocal renal tubular necrosis and mild cranioventral bronchointerstitial pneumonia (O'Toole, Brown, Bridges and Cartwright, 1989). In our study, no lesions were observed in other organs.

Location and Intensity of Viral Multiplication

The monoclonal antibody against the nucleoprotein was chosen for the more intense reaction obtained on acetone-fixed sections, compared with other monoclonal antibodies. The nucleoprotein seemed to be present in greatest amount in the infected cells, or more resistant to the denaturation of the fixative agent.

In 1-week-old pigs orally infected with the virulent Gep II or the Purdue-115 strains, TGE virus antigens were observed mainly in the enterocytes of the jejunum and ileum, in the cells of Peyer's patches and in the macrophages and reticular cells of the mesenteric lymph nodes. In the bronchiolar epithelial cells, alveolar macrophages and reticular cells and macrophages of the spleen, tonsil and kidney, the number of infected cells was low. Previous studies of the lungs of TGEV-infected piglets found virus in bronchial and bronchiolar cells and in pneumocytes (Underdahl, Mebus and Torres-Medina, 1975). Alveolar macrophages were proposed as a target cell population following infection *in vitro* by cell-adapted but not wild-type TGEV strains (Laude, Charley and Gelfi, 1984). The lungs of Purdue-115 infected pigs were negative.

The highly attenuated Nouzilly strain showed a tropism which was restricted to the caudal portion of the small intestine, usually to the ileum and, to a lesser extent, the jejunum. Infection of enterocytes by Nouzilly was less intense than with the Purdue-115 strain, which showed profuse infection in both the jejunum and ileum. As with any virulent or attenuated TGE strain, it hardly multiplied outside the intestinal mucosa, a little in Peyer's patches (M-cells), mesenteric and inguinal lymph nodes and tonsils (macrophages and reticular cells) and was absent in other organs (spleen, liver, kidney, tongue and lung).

It has been suggested (Bohl *et al.*, 1972; Saif and Bohl, 1979) that the attenuated strains of TGE induced a poor immunological stimulation of the small intestinal mucosa. Morilla and Ristic (1973) theorized that the lack of protection of the cell-passaged TGE virus may be more attributable to the absence of a necessary antigenic component, found only in pig intestinal virus,

than to an inability to replicate adequately in the animal. Different antigens in attenuated and virulent strains had already been described (Welch and Saif, 1988). Nevertheless the attenuated Nouzilly strain induced a sufficient immune response in lactating sows to protect sucking piglets against virulent virus challenge (Aynaud *et al.*, 1991). The support of the lactogenic immunity in this case was not solely explained by the secretory IgA which is not the predominant antibody class in milk (Bernard, Shirai, Lantier, Bottreau and Aynaud, 1990). The localization of the viral antigens in different organs (mesenteric and inguinal lymph nodes, tonsils, spleen, and others) was not sufficient to explain this particular immune property. These results suggested that mechanisms involved in TGE lactogenic immunity by the Nouzilly strain could be different from those with the virulent TGE virus strain.

To conclude, compared with the virulent Gep II and with the high passaged Purdue-115, the attenuated Nouzilly strain is wholly devoid of any virulence for newborn piglets. The explanation may lie in the slight multiplication in the cranial portion of the small intestine (jejunum). It only multiplies in the ileum and mesenteric lymph nodes. More studies with older animals may provide an explanation of the ability of the Nouzilly strain to induce a protective lactogenic immune response.

Acknowledgments

This work was supported in part by grants from the Department of Science and Technology of the Education and Science Ministry (Spain). We wish to thank Mr. R. Delaunay, D. Musset, Ph. Bernardet, for animal breeding, Mr. M. Olivier, Mrs. I. Lantier and H. Salmon for technical assistance, Mr. J. A. Navarro for advice in histopathology and Mr. J. M. Aynaud for helpful scientific discussion.

References

- Aynaud, J.M., Bernard, S., Bottreau, E., Lantier, I., Salmon, H. and Vannier, P. (1991). Induction of lactogenic immunity to transmissible gastroenteritis virus of swine using an attenuated coronavirus mutant able to survive in the physicochemical environment of the digestive tract. *Veterinary Microbiology*, **26**, 227–239.
- Aynaud, J.M., Nguyen, T.D., Bottreau, E., Brun, A. and Vannier, P. (1985). Transmissible gastroenteritis (TGE) of swine: survivor selection of TGE virus mutants in stomach juice of adult pigs. *Journal of General Virology*, **66**, 1911–1917.
- Bachmann, P.A. and Hess, R.G. (1978). Attempts to develop immunoprophylaxis for transmissible gastroenteritis of swine. II. Immunogenicity of strain B1 after serial passages. *Zentralblatt für Veterinärmedizin B.*, **25**, 52–61.
- Bernard, S., Lantier, I., Laude, H. and Aynaud, J.M. (1986). Detection of transmissible gastroenteritis coronavirus antigens by a sandwich ELISA assay technique. *American Journal of Veterinary Research*, **47**, 2441–2444.
- Bernard, S., Shirai, J., Lantier, I., Bottreau, E. and Aynaud, J.M. (1990). Lactogenic immunity to transmissible gastroenteritis (TGE) of swine induced by the attenuated Nouzilly strain of TGE virus: Passive protection of piglets and detection of serum and milk antibody classes by ELISA. *Veterinary Immunology and Immunopathology*, **24**, 37–47.
- Bohl, E.H. (1989). Transmissible gastroenteritis virus (Classical enteritic variant). In *Virus Infection of Porcines*. M.B. Pensaert, Ed., Elsevier Science Publishers, B.V., pp. 139–165.

- Bohl, E.H., Gupta, R.K., Olquin, M.V. and Saif, L.J. (1972). Antibody responses in serum, colostrum and milk of swine after infection or vaccination with transmissible gastroenteritis virus. *Infection and Immunity*, **6**, 289–301.
- Chu, R.D., Glock, R.D. and Ross, R.F. (1982). Application of peroxidase anti-peroxidase staining technique for detection of transmissible gastroenteritis virus in pigs. *American Journal of Veterinary Research*, **43**, 77–81.
- Frederick, G.T., Bohl, E.H. and Cross, R.F. (1976). Pathogenicity of an attenuated strain of transmissible gastroenteritis virus for newborn pigs. *American Journal of Veterinary Research*, **37**, 165–169.
- Furuuchi, S., Shimizu, Y. and Kumagai, T. (1979). Multiplication of low and high cell culture passaged strains of transmissible gastroenteritis virus in organs of newborn piglets. *Veterinary Microbiology*, **3**, 169–178.
- Furuuchi, S., Shimizu, Y. and Kumagai, T. (1975). Comparison of properties between virulent and attenuated strains of transmissible gastroenteritis virus. *National Institute of Animal Health Quarterly*, **15**, 159–164.
- Harada, K., Furuuchi, S., Kumagai, T. and Sasahara, J. (1969). Pathogenicity, immunogenicity and distribution of transmissible gastroenteritis virus in pigs. *National Institute of Animal Health Quarterly*, **9**, 185–192.
- Hess, R.G., Bachmann, P.A. and Hänichen, T. (1977). Attempts to develop immunoprophylaxis for transmissible gastroenteritis of swine. I. Pathogenicity of the B1 strain after serial passages. *Zentralblatt für Veterinärmedizin B*, **24**, 753–763.
- Hooper, B.E. and Haelterman, E.O. (1966). Concepts of pathogenesis and passive immunity in transmissible gastroenteritis in swine. *Journal of the American Veterinary Medical Association*, **149**, 1580–1586.
- Ingh van Den, H., Bara, J., Cornelisse, C.J. and Nap, M. (1987). Aneuploidy and expression of gastric-associated mucus antigens M1 and CEA in colorectal adenomas. *American Journal of Clinical Pathology*, **87**, 174–179.
- Kemeny, L.J., Wiltsey, V.L. and Riley, J.L. (1975). Upper respiratory infection of lactating sows with transmissible gastroenteritis virus following contact exposure to infected piglets. *Cornell Veterinarian*, **65**, 352–362.
- Laude, H., Chapsal, J.M., Gelfi, J., Labiau, S. and Grosclaude, J. (1986). Antigenic structure of transmissible gastroenteritis virus. I. Properties of monoclonal antibodies directed against virion proteins. *Journal of General Virology*, **67**, 119–130.
- Laude, H., Charley, B. and Gelfi, J. (1984). Replication of transmissible gastroenteritis coronavirus (TGEV) in swine alveolar macrophages. *Journal of General Virology*, **65**, 327–332.
- Moon, H.W., Norman, J.O. and Lambert, G. (1973). Age dependent resistance to transmissible gastroenteritis of swine (TGE). I Clinical signs and some mucosal dimensions in the small intestine. *Canadian Journal of Comparative Medicine and Veterinary Science*, **37**, 157–166.
- Morilla, A. and Ristic, M. (1973). Immunologic discrepancy between intestinal and cell culture viruses of transmissible gastroenteritis of swine. *American Journal of Veterinary Research*, **34**, 1533–1538.
- Motovski, A., Belopopska, P., Surtmadzhiev, K., Aleksieva, B. and Aleksandrov, M. (1985). Detection of a transmissible gastroenteritis coronavirus by an immunofluorescent contrast technique. *Veterinarnomeditsinski Nauki*, **22**, 9–14.
- Moxley, R.A. and Olson, L.R. (1989). Lesions of transmissible gastroenteritis virus infection in experimentally inoculated pigs sucking immunized sows. *American Journal of Veterinary Research*, **50**, 708–716.
- Nguyen, T.D., Bernard, S., Bottaureau, E., Lantier, I. and Aynaud, J.M. (1987). Etude comparée de trois souches du coronavirus de la gastroentérite transmissible: conditions de la réplication virale et de la synthèse des antigènes structuraux. *Annale de l'Institut Pasteur/Virologie*, **138**, 315–330.
- O'Tool, D., Brown, I., Bridges, A. and Cartwright, S.F. (1989). Pathogenicity of experimental infection with "pneumoenteric" porcine coronavirus. *Research in Veterinary Science*, **47**, 23–29.

- Pensaert, M.B., Burnstein, T. and Haelterman, E.O. (1970a). Cell culture-adapted SH strain of transmissible gastroenteritis virus in pigs. In vitro and in vivo studies. *American Journal of Veterinary Research*, **31**, 771-781.
- Pensaert, M.B., Haelterman, E.O. and Burnstein, T. (1970b). Transmissible gastroenteritis of swine. I. Immunofluorescence, histopathology and virus production in the small intestine through the course of infection. *Archiv für die gesamte Virusforschung*, **32**, 321-334.
- Saif, L.J. and Bohl, E.H. (1979). Role of secretory IgA in passive immunity of swine to enteric viral infections. In *Immunology of breast milk*. P.L. Ogra and D. Dayton, Eds, Raven Press, New York, pp. 237-248.
- Underdahl, N.R., Mebus, C.A. and Torres-Medina, A. (1975). Recovery of transmissible gastroenteritis virus from chronically infected experimental pigs. *American Journal of Veterinary Research*, **36**, 1473-1476.
- Welch, S.W. and Saif, L.J. (1988). Monoclonal antibodies to a virulent strain of transmissible gastroenteritis virus: comparison of reactivity with virulent and attenuated virus. *Archives of Virology*, **101**, 221-235.

[Received, May 29th, 1991
Accepted, September 27th, 1991]