

Activation of Astrocytes in the Spinal Cord of Mice Chronically Infected with a Neurotropic Coronavirus

NING SUN,* DANA GRZYBICKI,† RAYMOND F. CASTRO,‡ SEAN MURPHY,§ and STANLEY PERLMAN*‡¹

Departments of *Pediatrics, †Pathology, ‡Microbiology, and §Pharmacology, University of Iowa, Iowa City, Iowa 52242

Received July 5, 1995; accepted September 8, 1995

Mice infected with the neurotropic JHM strain of mouse hepatitis virus (MHV-JHM) develop a demyelinating encephalomyelitis several weeks after infection. Astrogliosis and infiltration of inflammatory cells are prominent findings in the brains and spinal cords of infected mice. In this report, astrocytes in infected spinal cords were analyzed for expression of three pleiotropic cytokines, TNF- α , IL-1 β , and IL-6; Type 2 nitric oxide synthase (iNOS); and MHC class I and II antigen. The data show that all three cytokines and iNOS are expressed by astrocytes in chronically infected spinal cords. These activated astrocytes are localized to areas of virus infection and demyelination, although most of the astrocytes expressing these proteins are not MHV-infected. MHC class I and II antigen can be detected in these spinal cords as well, but not in cells with the typical morphology of astrocytes. TNF- α , IL-6, and iNOS are also evident in the brains of mice with MHV-induced acute encephalitis, but in marked contrast to the results obtained with the chronically infected mice, most of the cells expressing these cytokines or iNOS had the morphology of macrophages or other mononuclear cells and very few appeared to be astrocytes. Additionally, astrocytes and, most likely, oligodendrocytes are infected in the spinal cords of mice with chronic demyelination. These results are consistent with a role for both viral infection of glial cells and high localized levels of proinflammatory cytokines and nitric oxide in the demyelinating process in mice infected with MHV-JHM. They also show that analogously to the human demyelinating disease, multiple sclerosis, astrocytes are a major cellular source for these cytokines in mice with chronic, but not acute disease. © 1995 Academic Press, Inc.

INTRODUCTION

The JHM strain of mouse hepatitis virus (MHV-JHM), a member of the coronavirus family, causes acute encephalomyelitis and acute and chronic demyelinating diseases in susceptible strains of mice and rats (Kyuwa and Stohlman, 1990). Infection with this virus results in a persistent infection of the central nervous system (CNS) and the disease process has some similarities with the human disease multiple sclerosis (MS). Mice with extensive amounts of demyelination are symptomatic, with hindlimb paralysis the most common clinical sign of disease. The most prominent histological lesion observed in the brains and spinal cords of infected animals is primary demyelination, with relative sparing of axons. An inflammatory infiltrate, consisting of T lymphocytes and macrophages, is present in the vicinity of the demyelinating lesions. Astrocytosis is also commonly observed adjacent to the lesions (Weiner, 1973).

Suckling C57Bl/6 mice inoculated intranasally with MHV-JHM invariably develop an acute, fatal encephalitis, with death occurring 6–7 days postinoculation (p.i.). If these infected mice are nursed by dams previously immunized to MHV-JHM, they are fully protected from the

acute encephalitis, but a variable percentage (40–90%) develop the chronic demyelinating disease described above. In these mice, evidence of active virus infection and inflammatory cell infiltration can be detected adjacent to areas of demyelination. Infectious virus can be isolated from the CNS of mice with symptoms, but not those which remain asymptomatic. Viral RNA and antigen can be detected in most mice and are abundant in the white matter of the spinal cord in animals with symptoms and extensive amounts of demyelination (Perlman *et al.*, 1987). The chronic disease also develops in mice infected with attenuated variants of MHV-JHM and in mice protected by passive infusions of antiviral antibodies or T cells (Haspel *et al.*, 1978; Buchmeier *et al.*, 1984; Dalziel *et al.*, 1986; Nakanaga *et al.*, 1986; Stohlman *et al.*, 1986, 1995a; Fleming *et al.*, 1989; Körner *et al.*, 1991; Yamaguchi *et al.*, 1991).

Viral lysis of oligodendrocytes is believed to be an important component of MHV-induced acute demyelination, although an immune response to virus-infected cells also appears to be involved in the pathogenic process in these mice (Lampert *et al.*, 1973; Weiner, 1973; Wang *et al.*, 1990). The pathogenesis of the chronic demyelinating disease is less well characterized. Many of the infected cells in the brains of these mice with chronic disease are astrocytes (Perlman and Ries, 1987). The astrocytes present in these mice have the morphological features of reactive cells, with intense immunohisto-

¹ To whom correspondence and reprint requests should be addressed at Department of Pediatrics, Medical Laboratories 207, University of Iowa, Iowa City, IA 52242. Fax: 319-356-4855.

chemical staining for glial fibrillary acidic protein (GFAP), a marker specific for astrocytes. GFAP is upregulated in other inflammatory processes as well (Hatten *et al.*, 1991; Eddleston and Mucke, 1993). Both cultured astrocytes and oligodendrocytes are readily infected by MHV (Knobler *et al.*, 1981; Massa *et al.*, 1986; Lavi *et al.*, 1987; Van Berlo *et al.*, 1989; Pasick and Dales, 1991; Gilmore *et al.*, 1994). MHC class I antigen expression is increased in astrocyte cultures infected for 3–5 days with MHV-JHM or the mildly neurotropic A59 strain of MHV (MHV-A59) (Suzumura *et al.*, 1986; Joseph *et al.*, 1990; Gilmore *et al.*, 1994), although in one of these studies, increased expression could only be detected in MHV-A59-infected cultures (Gilmore *et al.*, 1994). The results of these studies suggest that astrocytes are activated by exposure to MHV or to a cellular or viral protein secreted as a consequence of the infection.

Astrocytes are in close contact with oligodendrocytes and normal astrocyte function is required for the differentiation, proliferation, and survival of oligodendrocytes (Gard, 1993). In addition, cytokines, such as TNF- α , IL-1 β , and IL-6, important components of the immune response, are produced by astrocytes (Eddleston and Mucke, 1993; Gard, 1993). Cultured oligodendrocytes are susceptible to the toxic effects of tumor necrosis factor- α (TNF- α) secreted by reactive astrocytes (Selmaj and Raine, 1988; Lieberman *et al.*, 1989). TNF- α mRNA is expressed at high levels in the brains of mice acutely infected with MHV and experiments using immunosuppressed mice suggest that resident cells of the CNS, such as microglia and astrocytes, are responsible for the synthesis of this compound (Pearce *et al.*, 1994). Activated astrocytes also express Type 2 nitric oxide synthase (iNOS), an enzyme critical for the generation of nitric oxide (Simmons and Murphy, 1992). Nitric oxide has several biological functions and is considered an important effector in the immune response to specific pathogens. In addition, *in vitro* studies show that nitric oxide is cytotoxic to oligodendrocytes (Merrill *et al.*, 1993) and thus may be involved in the demyelinating process. Synthesis of iNOS is induced by such cytokines as TNF- α and IL-1 (Murphy *et al.*, 1993).

Therefore, the activation of astrocytes, either by inactivation of trophic function or by the secretion of toxic compounds, could contribute to oligodendrocyte dysfunction and consequently, the demyelinating process. With a few exceptions (Zheng *et al.*, 1993; Campbell *et al.*, 1994; Nagano *et al.*, 1994; Lipton and Gendelman, 1995), little is known about the cellular source of TNF- α , IL-1 β , IL-6, and nitric oxide in both acute and chronic viral infections of the CNS. For the purpose of determining if astrocytes were the source for these immunomodulatory molecules in chronically infected mice, brains and spinal cords harvested from mice with MHV-induced chronic demyelination were assayed *in situ* for TNF- β , IL-1 β , and IL-6, for iNOS, and for MHC class I and II antigen expres-

sion and the results were compared to similar measurements made on acutely infected brains.

MATERIALS AND METHODS

Animals and virus

Pathogen-free 6-week-old C57Bl/6 mice were purchased from Jackson Laboratories (Bar Harbor, ME). MHV-JHM, used in all studies, was grown and titered as previously described (Perlman *et al.*, 1987). To obtain mice with hindlimb paralysis, suckling C57Bl/6 mice were inoculated intranasally with virus (5×10^4 PFU MHV-JHM) at 10 days of age and were nursed by dams immunized to MHV-JHM (Perlman *et al.*, 1987). Under these conditions, mice are protected from the acute encephalitis, but a variable number develop a demyelinating encephalomyelitis characterized by hindlimb paralysis several weeks p.i. A total of 10 chronically infected, symptomatic mice were harvested at 16 to 45 days following intranasal inoculation of MHV-JHM. Animals were euthanized with an overdose of Nembutal and perfused with phosphate-buffered saline (PBS) via the left ventricle. Spinal cords from these animals were frozen in Tissue-Tek II O.C.T. medium (Miles Laboratory, Elkhart, IN) in acetone–dry ice and stored at -70° before sectioning. Four mice with MHV-JHM-induced acute encephalitis and two uninfected mice were also used in this study.

Antibodies

Rat anti-TNF- α (clone MP6-XT22) and anti-IL-6 (clone MP5-20F3) antibodies were purchased from PharMingen (San Diego, CA). Mouse anti-IL-1 β antibody (Catalog No. AB-406-NA) was purchased from R&D Systems, Inc. (Minneapolis, MN). Rabbit anti-iNOS antibody was purchased from Transduction Laboratories (Lexington, KY). Mouse anti-I-A^b (clone 25-9-17S) and anti-H-2K^b/H-2D^b (clone 20-8-4) antibodies were provided by Dr. M. Dailey, University of Iowa. Rabbit anti-human GFAP antibody was provided by Dr. L. Eng, Stanford University. Rat anti-macrophage antibody (F4/80 Cl: A3-1) was purchased from Serotec Bioproducts for Science, Inc. (Indianapolis, IN). A mouse monoclonal antibody raised against the N protein of MHV-JHM (MAb 5B188.2) was provided by Dr. M. Buchmeier, The Scripps Research Institute. Biotinylated or Texas Red-conjugated goat anti-rat, biotinylated goat anti-mouse, and biotinylated or FITC-conjugated goat anti-rabbit antibodies were purchased from Vector Laboratories (Burlingame, CA). Biotinylated rabbit anti-mouse IgG2a antibody was purchased from Zymed Laboratories (South San Francisco, CA).

Immunocytochemistry

Frozen sections of brains and spinal cords of infected and uninfected mice were analyzed by immunocytochemistry for GFAP, F4/80, TNF- α , IL-6, IL-1 β , iNOS,

MHV-JHM, and MHC class I and II antigen as previously described (Sun and Perlman, 1995). Sections were cut on a cryostat at 25–30 μm and mounted on silane-treated slides. Sections were then immediately fixed in 2.5–4% paraformaldehyde in phosphate-lysine buffer (PLP) at 4° for 30–45 min, washed with PBS, and treated with 5% normal goat or rabbit serum depending upon the source of the secondary antibodies. Sections were then incubated with one of the following dilutions of primary antibody: GFAP (1:500), F4/80 (1:50), TNF- α (1:200), IL-1 β (1:200), IL-6 (1:200), iNOS (1:100), I-A^b (1:200), H-2K^b/H-2D^b (1:200), or MHV-JHM (1:500) at 4° overnight. After incubation with biotinylated secondary antibodies (1:200 dilution), sections were treated with Vectastain ABC (Vector Laboratory, Burlingame, CA) used according to the manufacturer with 3,3'-diaminobenzidine (DAB) as the final substrate. Finally, sections were dehydrated, coverslipped, and examined under the microscope. No labeling was observed if CNS tissue from uninfected animals was processed with antibodies to MHV-JHM, TNF- α , IL-1 β , IL-6, or iNOS or if irrelevant antibodies were used as the primary antibodies in experiments analyzing MHV-infected CNS tissue. In agreement with previous results, analysis of uninfected CNS tissue revealed low levels of MHC class I antigen expression on endothelial and meningeal cells and the presence of a few scattered cells which lightly stained for MHC class II antigen (Matsumoto and Fujiwara, 1986; Vass *et al.*, 1986; Yong and Antel, 1992).

Double immunofluorescence assays

The expression of GFAP and either TNF- α or IL-6 was assessed simultaneously on frozen sections of the spinal cords using the same antibodies as described above. FITC-conjugated goat anti-rabbit antibody was used to detect GFAP and Texas Red-conjugated goat anti-rat antibody to detect TNF- α or IL-6. Sections were pretreated with 5% normal goat serum and then incubated in a mixture of anti-GFAP (1:200) and either anti-TNF- α (1:50–100) or anti-IL-6 (1:50–100) at 4° overnight or 2 hr at room temperature. Sections were then incubated in a mixture of secondary antibodies for 1 hr and washed with PBS. Slides were mounted using Vectashield medium (Vector Laboratories) prior to viewing with an Olympus BH-2 microscope with epifluorescence light excitation. No evidence for spillover between the two fluorescent tags was observed in control experiments. As negative controls, sections from the same spinal cords were processed in the absence of primary antibody. No labeling was observed in these sections.

In situ hybridization

Longitudinal sections from the spinal cords of mice with chronic demyelination and hindlimb paralysis were analyzed for MHV-JHM by *in situ* hybridization using an

antisense riboprobe as previously described (Perlman *et al.*, 1988, 1990). Sections were counterstained with cresyl violet following completion of the *in situ* hybridization.

Double-labeling immunocytochemistry and *in situ* hybridization

In situ hybridization using an antisense riboprobe for MHV RNA was combined with immunocytochemistry for GFAP, TNF- α , and IL-6 as previously described (Sun and Perlman, 1995). Briefly, coronal sections (25–30 μm) from the spinal cords of mice were cut with a cryostat and placed on silane-treated slides. Sections were fixed with 2.5% PLP and processed for immunocytochemistry followed by *in situ* hybridization as described above. Samples were then dipped in NTB-2 emulsion (Eastman Kodak, Rochester, NY) for 2 weeks. After development, slides were analyzed by light microscopy. The control experiments included omitting the primary antibodies or substituting an irrelevant antibody for the specific primary antibody.

RESULTS

Expression of TNF- α , IL-1 β , IL-6, iNOS, and MHC class I and II antigens within the brains and spinal cords of mice with either chronic demyelination or acute encephalitis

Suckling C57Bl/6 mice infected intranasally with MHV-JHM and nursed by dams immunized against the virus develop a clinically evident, chronic demyelinating encephalomyelitis 3–8 weeks after inoculation. Large, focal areas of demyelination are evident in the spinal cords of these mice and viral RNA and protein can be detected in the vicinity of the histological changes (Castro *et al.*, 1994). Viral antigen was present in the anterior and lateral parts of the white matter of the spinal cord, in agreement with previous results (Perlman *et al.*, 1990) (Fig. 1A). Reactive astrocytes identified using an anti-GFAP antibody (Fig. 1C) and macrophages/microglia (Fig. 1D) were readily detected in the spinal cords of these mice. Next, the spinal cords were examined for expression of three pleiotropic inflammatory cytokines, TNF- α , IL-1 β and IL-6, previously shown to be produced by activated astrocytes (Eddleston and Mucke, 1993). TNF- α (Figs. 1B, 2E, and 2F), IL-1 β (Fig. 1F), and IL-6 (Figs. 2C and 2D) could be identified in the gray and white matter of the spinal cord, although significantly more labeling was observed in the white matter. Examination of these sections at higher power showed that most of the cells labeled for these cytokines had the morphology of astrocytes (Figs. 1F, 2D, and 2F). These sections were also probed for iNOS and, as shown in Fig. 1E, this protein could be detected in cells with the appearance of astrocytes. In general, these cells were localized adjacent to demyelinating lesions although a

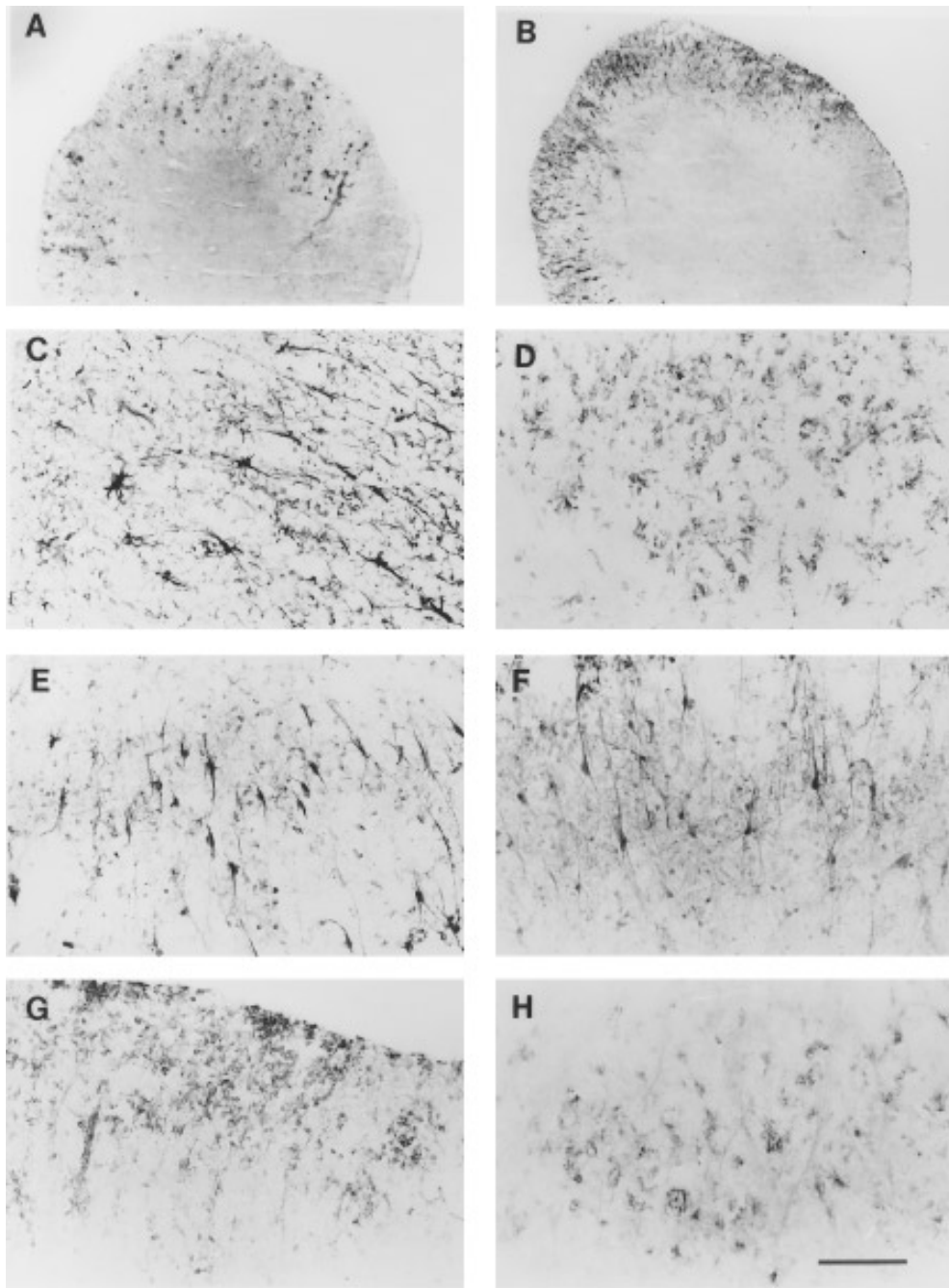


FIG. 1. Distribution of MHV-JHM antigen, astrocytes, macrophages, TNF- α , and IL-1 β , iNOS, and MHC class I and II antigens in the spinal cords of C57B1/6 mice with chronic demyelination. Spinal cords were harvested from mice with hindlimb paralysis and analyzed using immunocytochemistry as described under Materials and Methods. Shown in the figure are sections from mice harvested at 16, 21, 29, and 31 days p.i. (A and B) Low power views of MHV-JHM-infected spinal cords showing presence of viral antigen (A) and TNF- α (B) in the white matter. (C) Distribution of reactive astrocytes in the white matter identified using anti-GFAP antibody. (D) Distribution of macrophages in the white matter detected using MAb F4/80. (E and F) Distribution of cells expressing iNOS (E) and IL-1 β (F) in the white matter. (G and H) Distribution of MHC class I (G) and class II (H) antigen in the white matter of the spinal cord. Scale bar: A, B, 400 μ m; C, D, E, F, and H, 100 μ m; G, 200 μ m.

smaller number of these cells did not appear to be associated with such lesions (illustrated for TNF- α in Fig. 3). Some cells with the morphology of macrophages/microglia were also positive for TNF- α , IL-1 β , IL-6, and iNOS although they did not appear to be an important source of these immunomodulatory molecules in the

chronically infected mice. In the presence of irrelevant antibody, no staining was observed and these cytokines could not be detected in the spinal cords of uninfected mice (data not shown).

In the next experiments, we proved that the cells which expressed these inflammatory mediators and had the

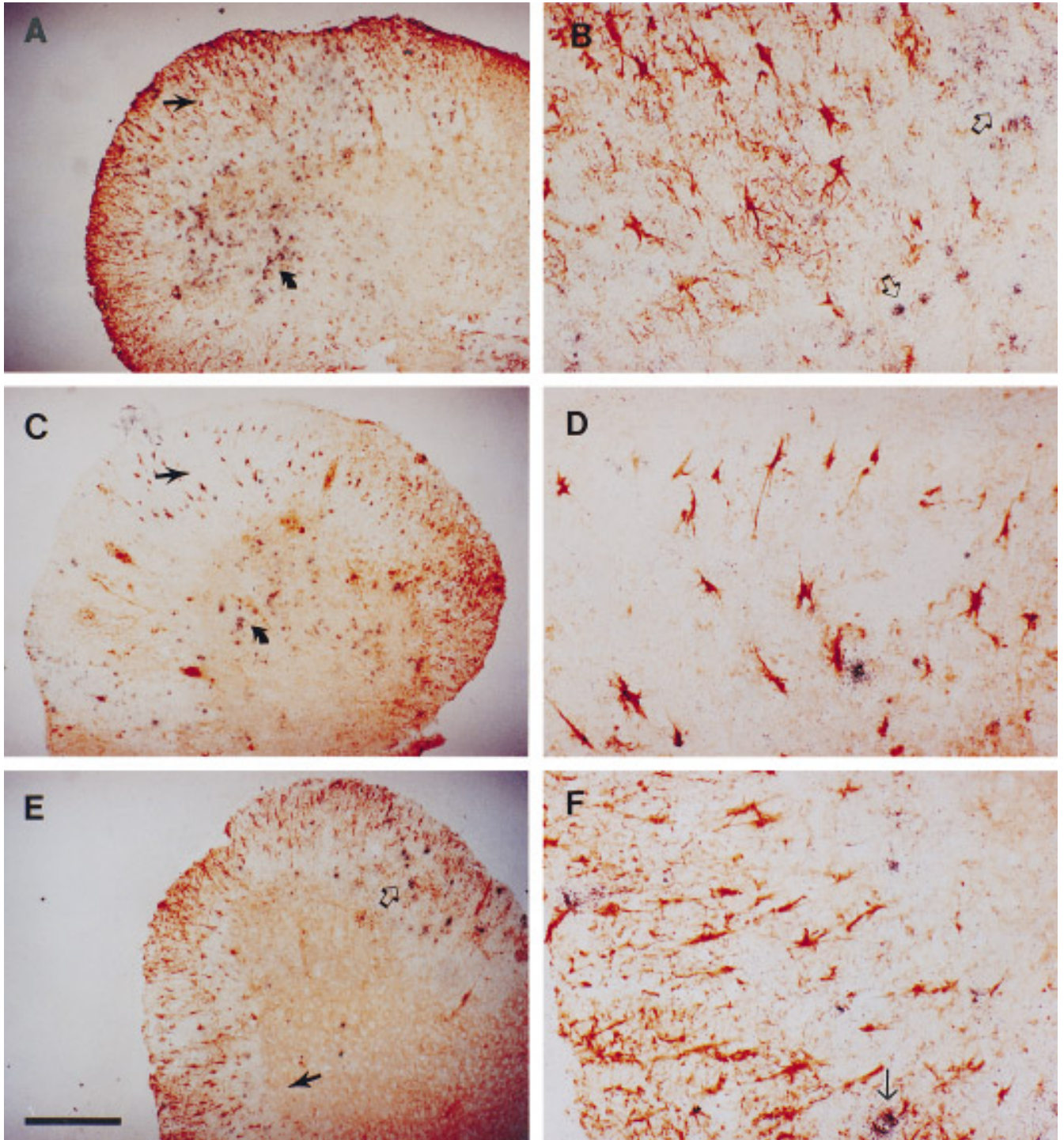


FIG. 2. Spatial relationship of MHV-JHM-infected cells to astrocytes expressing GFAP, IL-6, and TNF- α in the spinal cords of chronically infected mice. Samples from a mouse which developed hindlimb paralysis at 29 days p.i. were processed initially for GFAP (A and B), IL-6 (C and D), and TNF- α (E and F) using immunocytochemistry as described under Materials and Methods. MHV-JHM RNA was then assayed by *in situ* hybridization (silver grains). (A, C, and E) Low-power views of infected spinal cords showing relationship of infected cells to those expressing GFAP, IL-6, and TNF- α . Areas indicated by straight arrows in (A, C, and E) are shown at higher power in (B, D, and F). Viral mRNA was detected in both white (open arrows in B, and E) and gray (curved arrows in A and C) matter. An infected cell expressing TNF- α is indicated by a thin arrow in (F). Scale bar: A, C, and E, 200 μ m; B, D, and F, 50 μ m.

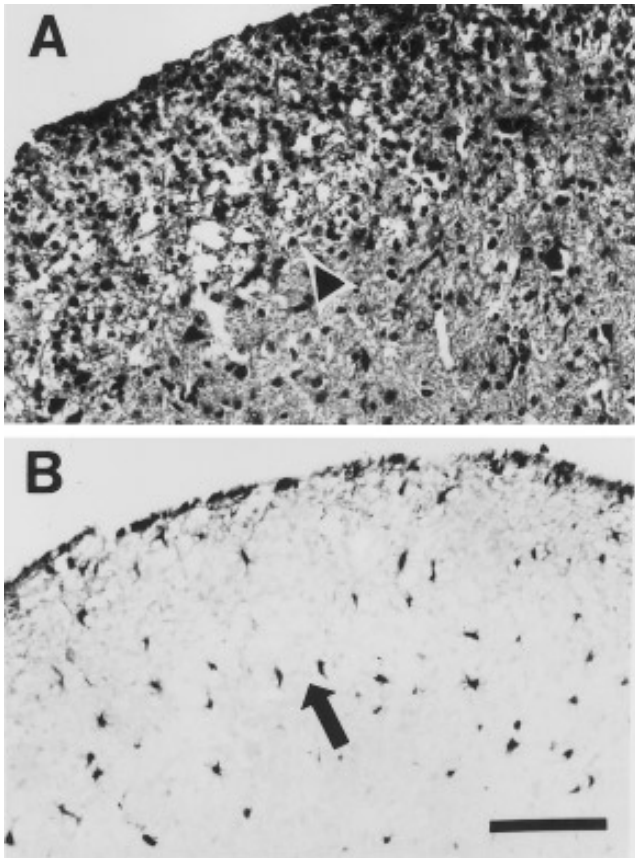


FIG. 3. Colocalization of astrocytes expressing TNF- α and demyelinating lesions. The brain and spinal cord from a mouse with hindlimb paralysis (29 days p.i.) was placed into Histochoice MB fixative (Amresco, Solon, OH) overnight prior to embedding in paraffin. Serial 15–20 μ M sections were cut and processed for staining with luxol fast blue (A) or for immunocytochemistry with TNF- α antibody (B). The same area of demyelination is indicated in (A) with an arrowhead and in (B) with an arrow. An extensive cellular infiltrate is apparent in the white matter (A). Astrocytes expressing TNF- α are present adjacent to the demyelinating lesion (B). Scale bar, 100 μ m.

morphology of astrocytes were in fact positive for GFAP. Two representative cytokines, TNF- α and IL-6, were analyzed, using a double immunofluorescence assay in which cells were assayed simultaneously for these cytokines and GFAP. As illustrated in Fig. 4, most of the cells which expressed TNF- α or IL-6 also expressed GFAP, showing that they were indeed astrocytes.

Cultured astrocytes have been shown to express MHC class I molecules after infection with MHV (Suzumura *et al.*, 1986; Joseph *et al.*, 1990; Gilmore *et al.*, 1994) and the results described above show that astrocytes are involved in the host response to MHV-JHM. Expression of MHC class I or II antigen on the surface of astrocytes would be consistent with a role for these cells in antigen presentation within the infected CNS. To determine if these molecules could be demonstrated on astrocytes, sections from infected spinal cords were probed with antibodies directed against H-2^b class I (D^b and K^b) and

class II (I-A^b) molecules. As shown in Figs. 1G and 1H, cells expressing MHC class I and II antigen were easily detected in infected spinal cords. However, the morphology of these cells did not appear to be that of astrocytes but, rather, suggested that the labeled cells were either macrophages or microglia (compare with Fig. 1D). In addition, MHC class I antigen could be detected on endothelial and meningeal cells (data not shown). These results suggest that if astrocytes with the morphology shown in Fig. 1C express either MHC class I or II antigen, then the level of expression is significantly lower than that present on other cells in the CNS of mice with demyelination.

Increased expression of TNF- α , IL-1 β , and IL-6 mRNA has also been reported in mice with MHV-JHM-induced acute encephalitis (Pearce *et al.*, 1994). Since mice with encephalitis die before virus spreads to the spinal cord, the midbrain and the brainstem of mice with the acute disease were assayed for GFAP and the three cytokines described above. GFAP (Fig. 5A), TNF- α (Fig. 5B), and IL-6 (Fig. 5C), but not IL-1 β (data not shown), were readily detected on these sections, with most of the cells positive for these molecules arranged in a perivascular distribution, as shown in Figs. 5B and 5C for TNF- α and IL-6, respectively. At present it is not known why IL-1 β could not be detected since IL-1 β mRNA expression has been shown to be upregulated in the brains of mice with acute encephalitis (Pearce *et al.*, 1994). Most of the cells expressing TNF- α , (Fig. 5B) or IL-6 (Fig. 5C) did not appear to be astrocytes (Fig. 5A), but rather had the morphology of macrophages or other mononuclear cells. Of interest, the only cells expressing iNOS also were macrophage-like (Gryzbicki *et al.*, manuscript in preparation). In a few cases, TNF- α or IL-6 could be detected in cells which appeared to be astrocytes, but this was uncommon (Fig. 5D). This is in marked contrast to the results shown in Figs. 1 and 2, in which the majority of cells expressing the three cytokines were astrocytes.

Spatial relationship between reactive astrocytes and MHV-infected cells in the spinal cords of mice with chronic demyelination

Previously, it was shown that many of the virus-infected cells in the brains of mice with chronic demyelination and hindlimb paralysis were astrocytes. From the results described thus far, it was not possible to discern whether the cells expressing the three cytokines were in fact infected or what the spatial relationship was between these cells and those infected with MHV-JHM. To answer these questions, sections were assayed sequentially for GFAP, TNF- α , or IL-6 by immunohistochemistry and for viral RNA by *in situ* hybridization as described under Materials and Methods. Astrocytes labeled for GFAP, TNF- α , and IL-6 were most apparent in the general vicinity of infected cells (positive for MHV RNA) although

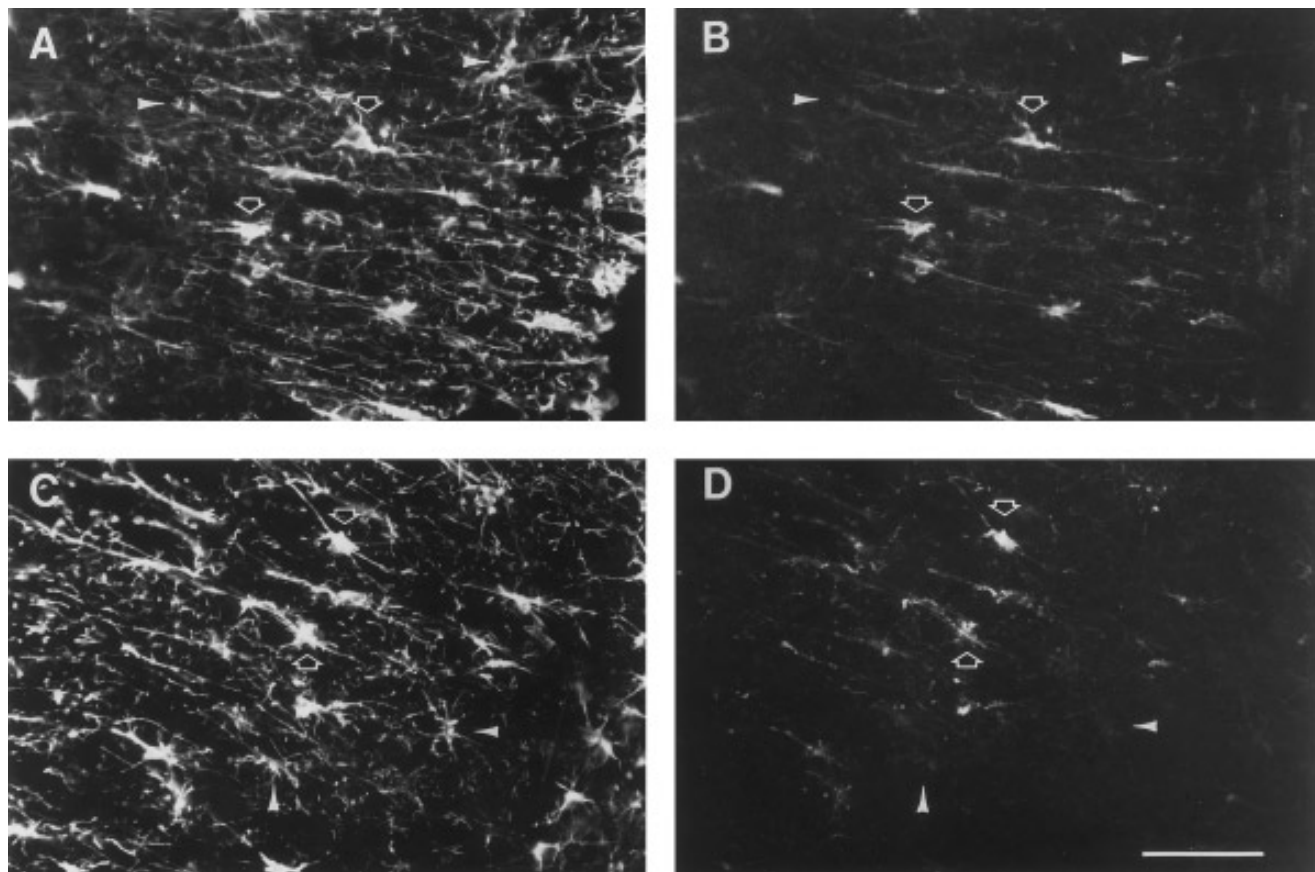


FIG. 4. Colocalization of GFAP with TNF- α and IL-6 in the white matter of spinal cords harvested from mice with chronic demyelination. Sections from the spinal cord of a mouse which developed hindlimb paralysis at 25 days p.i. were processed for double immunofluorescence labeling as described under Materials and Methods. (A and B) Section simultaneously processed for GFAP (A) and TNF- α (B). (C and D) Section simultaneously processed for GFAP (C) and IL-6 (D). Examples of doubly labeled cells are indicated by the open arrows. Arrowheads indicated cells labeled only by anti-GFAP antibody but not TNF- α or IL-6. Scale bar, 100 μ m.

fairly widespread expression of GFAP and the two cytokines was observed even when viral RNA could be detected only in focal accumulations (Figs. 2A, 2C, and 2E). Some of the cells expressing TNF- α or IL-6 were also infected with MHV-JHM (Fig. 2F). In general, however, most of the activated astrocytes were uninfected (Figs. 2B, 2D, and 2F).

Although most MHV-infected cells were present in the white matter, virus could, in some cases, be detected in the gray matter of the spinal cord. Some of these infected cells had the morphology of neurons. In these mice, TNF- α and IL-6 could also be detected in astrocytes in the gray matter (data not shown). This showed that activation of astrocytes occurred in all regions of active virus infection and was not confined to the white matter.

Both astrocytes and oligodendrocytes are infected in the white matter

In a previous report, the percentage of infected cells which were astrocytes was quantified using a dual immunohistochemistry-immunofluorescence assay. These measurements were made on the brains of infected mice

(Perlman and Ries, 1987). To determine if the same percentage of infected cells in the spinal cord were astrocytes as was reported previously for the brain, the percentage of infected, GFAP-positive cells in the gray and white matter of mice with chronic demyelination was determined. For these analyses, approximately 2600 MHV-JHM-infected cells in the gray and white matter of two spinal cords were examined. Of these, 211 cells (14.9%) in the white matter and 210 cells (17.4%) in the gray matter were positive for GFAP and therefore were astrocytes. This percentage is lower than previously determined in the analysis of chronically infected brains. In those experiments, 39% of brain-derived MHV-positive cells were astrocytes. Whether this reflects differences between mice, between the brain and spinal cord, or between the different methodologies used in the two experiments is not known.

Infection of oligodendrocytes is an important part of the pathogenic process in MHV-infected mice and with acute demyelination (Lampert *et al.*, 1973; Weiner, 1973; Powell and Lampert, 1975). Therefore, experiments were performed to determine if oligodendrocytes were similarly

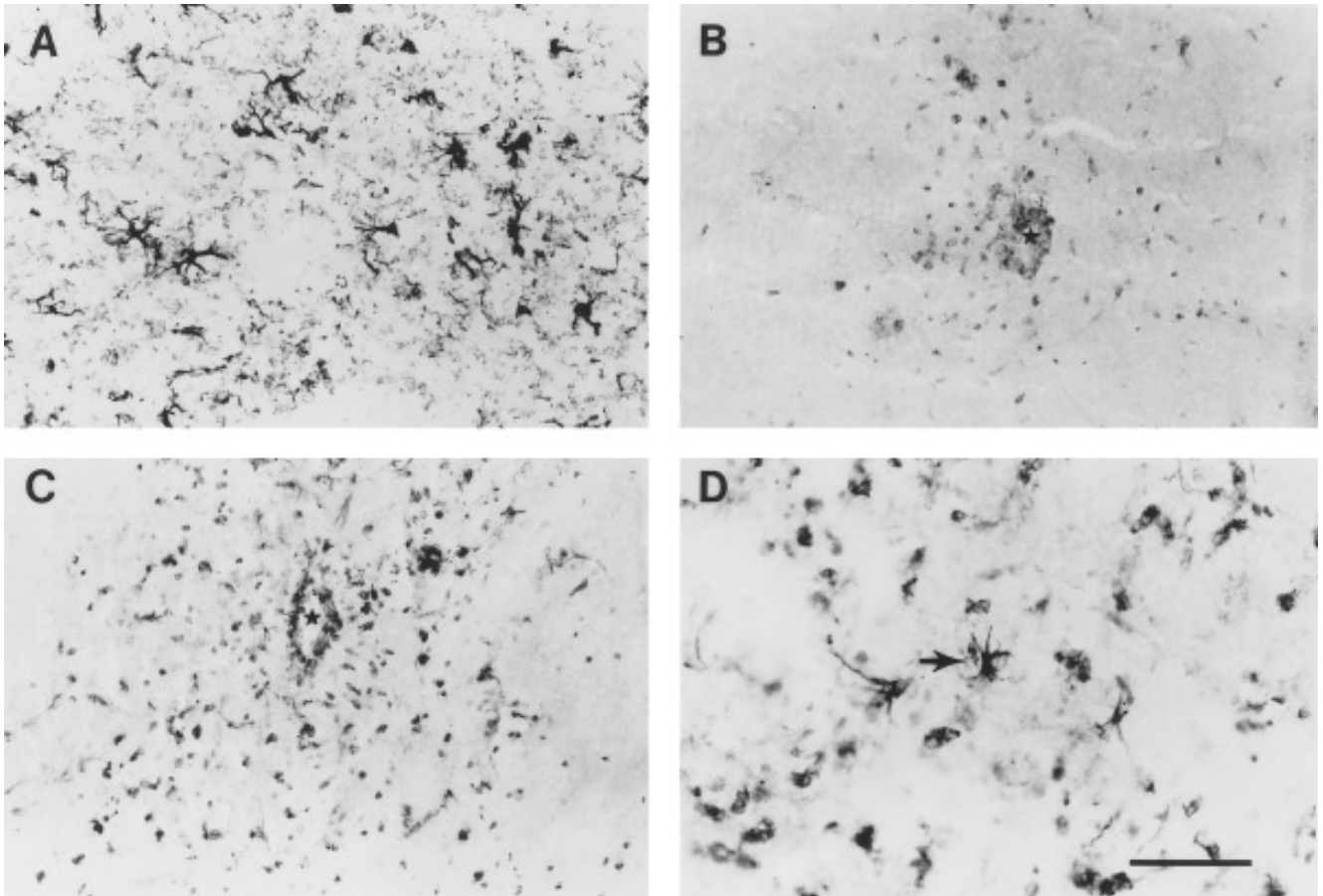


FIG. 5. Detection of TNF- α and IL-6 in the brains of mice with MHV-JHM-induced acute encephalitis. Six-week-old C57B1/6 mice were infected intranasally with MHV-JHM and brains were harvested at 6 days p.i. when mice exhibited signs of severe encephalitis. Sections were processed using immunocytochemistry as described under Materials and Methods. (A) GFAP-positive reactive astrocytes. (B–D) Detection of cells labeled for TNF- α (B) and IL-6 (C and D). TNF- α (B) and IL-6 (C) positive cells were detected in a perivascular distribution (*indicates a blood vessel). The majority of TNF- α - and IL-6-positive cells appear to be macrophages or other mononuclear cells (B–D). Occasional labeled cells with the morphology of astrocytes were also identified (black arrow in D). Scale bar: A–C, 100 μ m; D, 50 μ m.

infected in mice with the chronic demyelinating disease. The percentage of infected cells which were oligodendrocytes was difficult to determine since we and others have been unable to identify an antibody which consistently labels this type of glia (Lipton *et al.*, 1995). However, interfascicular oligodendrocytes in the white matter are organized into regularly spaced stretches of cells lying in direct contact with each other, forming rows in the longitudinal axis of the cord. To determine if cells with this pattern were labeled in the spinal cords of infected mice, longitudinal sections were cut and analyzed for MHV-JHM by *in situ* hybridization. The cellular architecture of the spinal cord was disrupted as a consequence of the infectious process, so long rows of cells were not apparent. However, short rows of these cells could be identified and were shown to be infected with MHV-JHM (Fig. 6). Assuming that these cells were in fact oligodendrocytes, these results suggest that infection of oligodendrocytes is involved in the pathogenic process in mice with chronic demyelination and hindlimb paralysis.

DISCUSSION

The demyelinating disease caused by MHV-JHM appears to be at least in part immune-mediated and various immunomodulatory molecules are likely to be part of the pathogenic process. The objective of this report was to determine the extent to which astrocytes were the cellular source of these molecules. In this study, brains and spinal cords harvested from mice with either acute encephalitis or chronic demyelination were analyzed for the expression of three pleiotropic cytokines, TNF- α , IL-1 β , and IL-6, and the inducible isoform of NOS. TNF- α , IL-1 β , IL-6, and nitric oxide were chosen for study because they are pivotal in the host response to injury in the CNS, have broad ranges of activity, and are produced by cultured astrocytes (Hartung *et al.*, 1992; Morganti-Kossmann *et al.*, 1992; Simmons and Murphy, 1992). While all three cytokines (with the exception of IL-1 β in mice with acute encephalitis) and iNOS were detected in the CNS in both diseases, the predominant cell type labeled

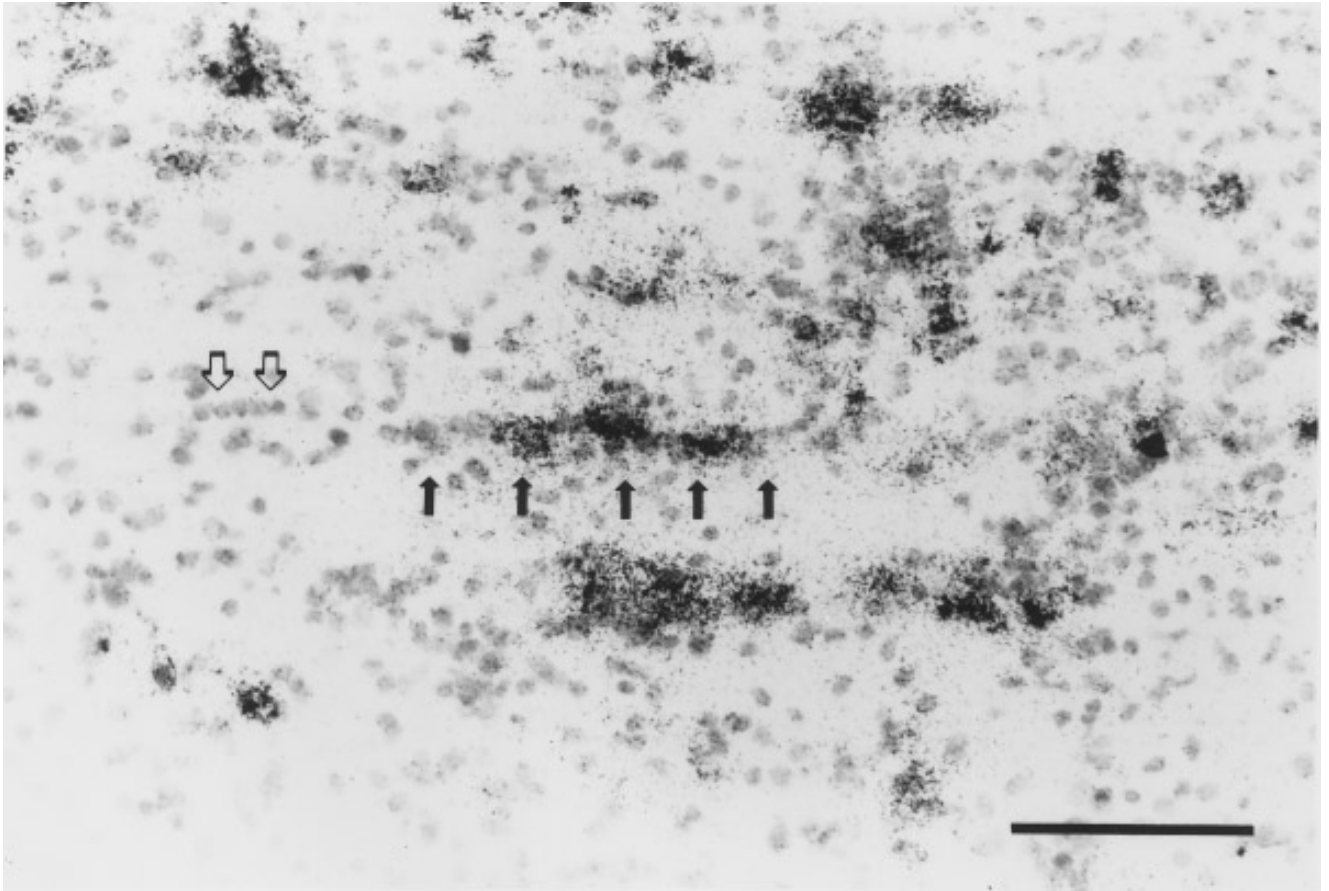


FIG. 6. Probable MHV-JHM infection of oligodendrocytes in mice with chronic demyelination. Longitudinal sections of a spinal cord harvested from a mouse which developed hindlimb paralysis at 32 days p.i. were analyzed for viral RNA using in situ hybridization as described under Materials and Methods. Samples were counterstained with cresyl violet. Viral RNA is indicated by the presence of silver grains. Uninfected interfascicular oligodendrocytes are organized in a unique linear pattern (open arrows). Viral RNA colocalized with some of these cells (black arrows). Scale bar, 100 μm .

for each protein differed between the two. Expression by astrocytes was prominent only in mice with chronic demyelination and activated astrocytes were located adjacent to areas of virus infection and demyelination (Figs. 1–3). This labeling for cytokines or iNOS could represent either *de novo* synthesis by astrocytes or production elsewhere and subsequent uptake of these molecules by astrocytes. We favor the former interpretation for two reasons. First, astrocytes are the predominant cell labeled for all three cytokines and iNOS. If these molecules were synthesized by other cells, these cells should also be labeled in the sections. Second, iNOS is not secreted, making it unlikely that the enzyme was produced by other cells and taken up by astrocytes. In addition, expression of all three cytokines and iNOS has been well documented in experiments in which cultured astrocytes were activated *in vitro* (Simmons and Murphy, 1992; Eddleston and Mucke, 1993). Our data represent one of the few examples in which apparent synthesis of all of these cytokines and iNOS by astrocytes is documented *in situ* and are consistent with the notion that this synthesis

is an important part of the inflammatory response and demyelination in the CNS.

These results are in marked contrast to what is observed in mice with acute encephalitis, in which TNF- α , IL-6, and iNOS were primarily detected in cells with the morphology of mononuclear cells. These cells were observed to radiate from large blood vessels, consistent with production by infiltrating, blood-derived cells (Fig. 5). Mononuclear cell perivascular infiltration is one of the early pathological changes described in mice infected with MHV-JHM (Weiner, 1973), and our results suggest that these cells produce cytokines and iNOS as part of the initial response to the virus. These results are consistent with a recent study in which macrophages and microglia were shown to produce TNF- α in mice with experimental allergic encephalomyelitis (Renno *et al.*, 1995) as well as other reports showing that infiltrating mononuclear cells but not resident CNS cells produced iNOS in animals with virus-induced acute encephalitis (Zheng *et al.*, 1993; Campbell *et al.*, 1994). Of note, in our study, large numbers of macrophages/microglia were

present in the CNS of mice with hindlimb paralysis, but most of these cells did not express the three cytokines or iNOS at levels comparable to what was observed in acutely infected mice. Macrophages have been shown to strip myelin sheaths off axons in MHV-JHM-infected mice with extensive demyelination (Powell and Lampert, 1975). Therefore, it is possible that macrophages have different roles in the acute and chronic infections.

The pathogenesis of demyelination induced by MHV-JHM has similarities with the pathogenic process observed in the brains of patients with MS. In both cases, inflammatory infiltrates and astrogliosis are associated with active lesions (Lee *et al.*, 1990; Raine, 1994). TNF- α and iNOS are expressed by astrocytes associated with the lesions in both cases (Hofman *et al.*, 1989; Selmaj *et al.*, 1991; Bo *et al.*, 1994a). TNF- α and IL-1, but not IL-6, can be detected in the cerebrospinal fluid of patients with MS and MHC class II expression is upregulated in the CNS of both diseased humans and mice (Hauser *et al.*, 1990). In MS, MHC class II is only rarely, if ever, seen on reactive astrocytes (Bo *et al.*, 1994b) and in our study, no expression of either MHC class I or II antigen could be detected on cells with the typical morphology of astrocytes (compare Figs. 1C, 1G, and 1H). A caveat to our experiments is that astrocytes may express MHC class I or II molecules at physiological levels below the level of detection of the immunohistochemical assay, although expression of these molecules on other cell types could clearly be detected. In a previous study, MHC class I antigen expression was detected on astrocytes isolated from the brains of 7- to 9-day-old mice infected with MHV-A59 (Suzumura *et al.*, 1986). Isolation of astrocytes from older mice is more difficult and we do not know if astrocytes removed from the brains of mice chronically infected with MHV-JHM and analyzed immediately in cell culture would also express MHC class I antigen. Our data are consistent with a recent report in which the constitutive expression of MHC class I antigen by astrocytes was inhibited in cultures persistently infected with MHV-JHM (Gilmore *et al.*, 1994) and raise the possibility that persistent infection with MHV-JHM in mice leads to an active suppression rather than a lack of induction of MHC antigen expression. Thus, these results suggest that astrocytes have a role in the propagation of the immunopathologic process in both the human and murine diseases, but do not present antigen to lymphocytes and do not participate in the initiation of the immune response.

TNF- α , IL-1 β , and IL-6 are all involved in the development of a normal inflammatory response and protective immunity. IL-1 β , considered an important mediator of inflammation in the CNS, functions at least in part by increasing expression of ICAM-1 and thereby enhancing adhesion of leukocytes to endothelial cells (Ken-Ichi *et al.*, 1990). TNF- α also helps mediate the inflammatory response, partly by stimulating the synthesis of other

cytokines by many cell types and by increasing vascular permeability and expression of adhesion molecules (Tracey and Cerami, 1993). IL-6, among other functions, is involved in the proliferation and differentiation of cytotoxic T cells (Akira *et al.*, 1993). IL-1 and TNF- α induce the synthesis of iNOS (Murphy *et al.*, 1993). While the role of each cytokine in the pathogenic process and the extent to which they affect the level and function of each other is not well understood, maintenance of a chronic inflammatory response likely requires the continued synthesis of one or more of these cytokines. It is striking that the source for these cytokines and iNOS shifted from macrophages/microglia to a preponderance of astrocytes as the MHV infection changed from an acute to a chronic phase. Cytokine production by astrocytes may be a general feature of chronic viral infections since such production by astrocytes has also been documented at autopsy in patients with subacute sclerosing panencephalitis (Nagano *et al.*, 1994). The basis for the predominant synthesis of cytokines by astrocytes and not macrophages in chronically infected mice remains to be determined. However, expression of TNF- α and nitric oxide by astrocytes located adjacent to demyelinating lesions might contribute to the process of demyelination since both independently are toxic for oligodendrocytes (Selmaj and Raine, 1988; Merrill *et al.*, 1993). No data are available yet defining the precise role of either TNF- α or nitric oxide in MHV-JHM-induced chronic demyelination, although, in a recent study, treatment with neutralizing antibodies to TNF- α did not affect this process in mice with MHV-induced acute demyelination (Stohman *et al.*, 1995b).

As in mice with acute demyelination (Lampert *et al.*, 1973; Powell and Lampert, 1975), oligodendrocytes appear to be infected in mice with chronic demyelination and hindlimb paralysis (Fig. 6). Astrocytes are also infected in the CNS of mice with chronic demyelination, although they did not account for the majority of infected cells in the brain (Perlman and Ries, 1987) or the white or gray matter of the spinal cord. Whether the remainder are macrophages, microglia or neurons is being investigated at present.

These results are consistent with roles both for a direct effect of MHV-JHM on the function of oligodendrocytes and astrocytes and for immune-mediated destruction in the chronic demyelinating disease. Astrocytes localized adjacent to areas of virus infection clearly produce cytokines and iNOS which are important for the antiviral immune response but are also likely to contribute to the pathogenic process. Although these immunomodulatory molecules have overlapping activities, use of transgenic mice deficient in the production of one or more of them should allow elucidation of their roles in MHV-induced demyelination.

ACKNOWLEDGMENTS

We thank Drs. C. M., Stoltzfus and M. Dailey for critical review of the manuscript and Paul Reimann for photographic assistance. This

research was supported by NIH Grants NS24401 (S.P.) and NS 29226 (S.M.). N.S. was supported by NIH Training Grant T32AI07343 and D.G. by Training Grant NS 07294.

REFERENCES

- Akira, S., Taga, T., and Kishimoto, T. (1993). Interleukin-6 in biology and medicine. *Adv. Immunol.* **54**, 1–78.
- Bo, L., Dawson, T., Wesselingh, S., Mork, S., Choi, S., Kong, P. A., Hanley, D., and Trapp, B. D. (1994a). Induction of nitric oxide synthase in demyelinating regions of multiple sclerosis brains. *Ann. Neurol.* **36**, 778–786.
- Bo, L., Mork, S., Kong, P., Nyland, H., Pardo, C., and Trapp, B. D. (1994b). Detection of MHC class II-antigens on macrophages and microglia, but not on astrocytes and endothelia in active multiple sclerosis lesions. *J. Neuroimmunol.* **51**, 135–146.
- Buchmeier, M. J., Lewicki, H. A., Talbot, P. J., and Knobler, R. L. (1984). Murine hepatitis virus-4 (strain JHM)-induced neurologic disease is modulated *in vivo* by monoclonal antibody. *Virology* **132**, 261–270.
- Campbell, I., Samimi, A., and Chiang, C.-S. (1994). Expression of the inducible nitric oxide synthase. Correlation with neuropathology and clinical features in mice with lymphocytic choriomeningitis. *J. Immunol.* **153**, 3622–3629.
- Castro, R. F., Evans, G. D., Jaszewski, A., and Perlman, S. (1994). Coronavirus-induced demyelination occurs in the presence of virus-specific cytotoxic T cells. *Virology* **200**, 733–743.
- Dalziel, R. G., Lampert, P. W., Talbot, P. J., and Buchmeier, M. J. (1986). Site-specific alteration of murine hepatitis virus type 4 peplomer glycoprotein E2 results in reduced neurovirulence. *J. Virol.* **59**, 463–471.
- Eddleston, M., and Mucke, L. (1993). Molecular profile of reactive astrocytes—Implications for their role in neurologic disease. *Neuroscience* **54**, 15–36.
- Fleming, J. O., Shubin, R. A., Sussman, M. A., Casteel, N., and Stohlman, S. A. (1989). Monoclonal antibodies to the matrix (E1) glycoprotein of mouse hepatitis virus protect mice from encephalitis. *Virology* **168**, 162–167.
- Gard, A. L. (1993). Astrocyte-oligodendrocyte interactions. In "Astrocytes: Pharmacology and Function" (S. Murphy, Ed.), pp. 331–354. Academic Press, San Diego.
- Gilmore, W., Correale, J., and Weiner, L. (1994). Coronavirus induction of class I major histocompatibility complex expression in murine astrocytes is virus strain specific. *J. Exp. Med.* **180**, 1013–1023.
- Hartung, H.-P., Jung, S., Stoll, G., Zielasek, J., Schmidt, B., Archelos, J., and Toyka, K. V. (1992). Inflammatory mediators in demyelinating disorders of the CNS and PNS. *J. Neuroimmunol.* **40**, 197–210.
- Haspel, M. V., Lampert, P. W., and Oldstone, M. B. A. (1978). Temperature-sensitive mutants of mouse hepatitis virus produce a high incidence of demyelination. *Proc. Natl. Acad. Sci. USA* **75**, 4033–4036.
- Hatten, M., Liem, R., Shelanski, M., and Mason, C. (1991). Astroglia in CNS injury. *Glia* **4**, 233–243.
- Hauser, S., Doolittle, T., Lincoln, R., Brown, R. H., and Dinarello, C. A. (1990). Cytokine accumulations in CSF of multiple sclerosis patients: Frequent detection of interleukin-1 and tumor necrosis factor but not interleukin-6. *Neurology* **40**, 1735–1739.
- Hofman, F. M., Hinton, D. R., Johnson, K., and Merrill, J. E. (1989). Tumor necrosis factor identified in multiple sclerosis brain. *J. Exp. Med.* **170**, 607–612.
- Joseph, J., Knobler, R., Lublin, F., and Hart, M. (1990). Regulation of MHC class I and II antigens on cerebral endothelial cells and astrocytes following MHV-4 infection. *Adv. Exp. Med. Biol.* **279**, 579–591.
- Ken-Ichi, A., Lee, F., Miyajima, A., Shoichiro, M., Arai, N., and Yokota, T. (1990). Cytokines: Coordinators of immune and inflammatory responses. *Annu. Rev. Biochem.* **59**, 783–836.
- Knobler, R. L., Dubois-Dalq, M., Haspel, M. V., Claysmith, A. P., Lampert, P. W., and Oldstone, M. B. A. (1981). Selective localization of wild type and mutant mouse hepatitis (JHM strain) antigens in CNS tissue by fluorescence, light and electron microscopy. *J. Neuroimmunol.* **1**, 81–92.
- Körner, H., Schliephake, A., Winter, J., Zimprich, F., Lassmann, H., Sedgwick, J., Siddell, S., and Wege, H. (1991). Nucleocapsid or spike protein-specific CD4⁺ T lymphocytes protect against coronavirus-induced encephalomyelitis in the absence of CD8⁺ T cells. *J. Immunol.* **147**, 2317–2323.
- Kyuwa, S., and Stohlman, S. A. (1990). Pathogenesis of a neurotropic murine coronavirus, strain JHM in the central nervous system of mice. *Semin. Virol.* **1**, 273–280.
- Lampert, P. W., Sims, J. K., and Kniazeff, A. J. (1973). Mechanism of demyelination in JHM virus encephalomyelitis. *Acta Neuropathol.* **24**, 76–85.
- Lavi, E., Suzumura, A., Hirayama, M., Highkin, M. K., Dambach, D., Silberberg, D. H., and Weiss, S. R. (1987). Coronavirus mouse hepatitis virus (MHV)-A59 causes a persistent productive infection in primary glial cell cultures. *Microb. Pathog.* **3**, 79–86.
- Lee, S. C., Moore, G. R. W., Golenswsky, G., and Raine, C. S. (1990). Multiple sclerosis: A role for astroglia in active demyelination suggested by class II MHC expression and ultrastructural study. *J. Neuropathol. Exp. Neurol.* **49**, 122–136.
- Lieberman, A. P., Pitha, P., Shin, H., and Shin, M. (1989). Production of tumor necrosis factor and other cytokines by astrocytes stimulated with lipopolysaccharide or a neurotropic virus. *Proc. Natl. Acad. Sci. USA* **86**, 6348–6352.
- Lipton, S. A., and Gendelman, H. E. (1995). Dementia associated with the acquired immunodeficiency syndrome. *New Engl. J. Med.* **332**, 934–940.
- Lipton, H. L., Twaddle, G., and Jelachich, M. L. (1995). The predominant virus antigen burden is present in macrophages in Theiler's murine encephalomyelitis virus-induced demyelinating disease. *J. Virol.* **69**, 2525–2533.
- Massa, P. T., Wege, H., and ter Meulen, V. (1986). Analysis of murine hepatitis virus (JHM strain) tropism toward Lewis rat glial cells *in vitro*. *Lab. Invest.* **55**, 318–327.
- Matsumoto, Y., and Fujiwara, M. (1986). In situ detection of class I and II major histocompatibility complex antigens in the rat central nervous system during experimental allergic encephalomyelitis. An immunohistochemical study. *J. Neuroimmunol.* **12**, 265–277.
- Merrill, J. E., Ignarro, L. J., Sherman, M. P., Melinek, J., and Lane, T. E. (1993). Microglial cell cytotoxicity of oligodendrocytes is mediated through nitric oxide. *J. Immunol.* **151**, 2132–2141.
- Morganti-Kossmann, M. C., Kossman, T., and Wahl, S. M. (1992). Cytokines and neuropathology. *Trends Neurosci.* **13**, 286–291.
- Murphy, S., Simmons, M. L., Agullo, L., Garcia, A., Feinstein, D. L., Galea, E., Reis, D. J., Minc-Golomb, D., and Schwartz, J. P. (1993). Synthesis of nitric oxide in CNS glial cells. *Trends Neurosci.* **16**, 323–328.
- Nagano, I., Nakamura, S., Yoshioka, M., Onodera, J., Kogure, K., and Itoyama, Y. (1994). Expression of cytokines in brain lesions in subacute sclerosing panencephalitis. *Neurology* **44**, 710–715.
- Nakanaga, K., Yamanouchi, K., and Fujiwara, K. (1986). Protective effect of monoclonal antibodies on lethal mouse hepatitis virus infection in mice. *J. Virol.* **59**, 168–171.
- Pasick, J., and Dales, S. (1991). Infection by coronavirus JHM of rat neurons and oligodendrocytes-Type-2 astrocyte lineage cells during distinct developmental stages. *J. Virol.* **65**, 5013–5028.
- Pearce, B. D., Hobbs, M. V., McGraw, T. S., and Buchmeier, M. J. (1994). Cytokine induction during T-cell-mediated clearance of mouse hepatitis virus from neurons *in vivo*. *J. Virol.* **68**, 5483–5495.
- Perlman, S., and Ries, D. (1987). The astrocyte is a target cell in mice persistently infected with mouse hepatitis virus, strain JHM. *Microb. Pathog.* **3**, 309–314.
- Perlman, S., Evans, G., and Afifi, A. (1990). Effect of olfactory bulb ablation on spread of a neurotropic coronavirus into the mouse brain. *J. Exp. Med.* **172**, 1127–1132.
- Perlman, S., Jacobsen, G., and Moore, S. (1988). Regional localization

- of virus in the central nervous system of mice persistently infected with murine coronavirus JHM. *Virology* **166**, 328–338.
- Perlman, S., Jacobsen, G., Olson, A. L., and Afifi, A. (1990). Identification of the spinal cord as a major site of persistence during chronic infection with a murine coronavirus. *Virology* **175**, 418–426.
- Perlman, S., Schelper, R., Bolger, E., and Ries, D. (1987). Late onset, symptomatic, demyelinating encephalomyelitis in mice infected with MHV-JHM in the presence of maternal antibody. *Microb. Pathog.* **2**, 185–194.
- Powell, H. C., and Lampert, P. W. (1975). Oligodendrocytes and their myelin-plasma membrane connections in JHM mouse hepatitis virus encephalomyelitis. *Lab. Invest.* **33**, 440–445.
- Raine, C. S. (1994). Multiple sclerosis: Immune system molecule expression in the central nervous system. *J. Neuropathol. Exp. Neurol.* **53**, 328–337.
- Renno, T., Krakowski, M., Piccirillo, C., Lin, J.-Y., and Owens, T. (1995). TNF- α expression by resident microglia and infiltrating leukocytes in the central nervous system of mice with experimental allergic encephalomyelitis. *J. Immunol.* **154**, 339–346.
- Selmaj, K., and Raine, C. S. (1988). Tumor necrosis factor mediates myelin and oligodendrocyte damage in vitro. *Ann. Neurol.* **23**, 339–346.
- Selmaj, K., Raine, C. S., Cannella, B., and Brosnan, C. (1991). Identification of lymphotoxin and tumor necrosis factor in multiple sclerosis lesions. *J. Clin. Invest.* **87**, 949–954.
- Simmons, M. L., and Murphy, S. (1992). Induction of nitric oxide synthase in glial cells. *J. Neurochem.* **59**, 897–905.
- Stohman, S. A., Bergmann, C. C., van der Veen, R. C., and Hinton, D. R. (1995a). Mouse hepatitis virus-specific cytotoxic T lymphocytes protect from lethal infection without eliminating virus from the central nervous system. *J. Virol.* **69**, 684–694.
- Stohman, S. A., Hinton, D. R., Cua, D., Dimacali, E., Sensintaffar, J., Hofman, F. M., Tahara, S. M., and Yao, Q. (1995b). Tumor necrosis factor expression during mouse hepatitis virus-induced demyelinating encephalomyelitis. *J. Virol.* **69**, 5898–5903.
- Stohman, S. A., Matsushima, G. K., Casteel, N., and Weiner, L. P. (1986). In vivo effects of coronavirus-specific T cell clones: DTH inducer cells prevent a lethal infection but do not inhibit virus replication. *J. Immunol.* **136**, 3052–3056.
- Sun, N., and Perlman, S. (1995). Spread of a neurotropic coronavirus to spinal cord white matter via neurons and astrocytes. *J. Virol.* **69**, 633–641.
- Suzumura, A., Lavi, E., Weiss, S. R., and Silberberg, D. H. (1986). Coronavirus infection induces H-2 antigen expression on oligodendrocytes and astrocytes. *Science* **232**, 991–993.
- Tracey, K. J., and Cerami, A. (1993). Tumor necrosis factor, other cytokines and disease. *Annu. Rev. Cell Biol.* **9**, 317–343.
- Van Berlo, M., Warringa, R., Wolswijk, G., and Lopes-Cardozo, M. (1989). Vulnerability of rat and mouse brain cells in murine hepatitis virus (JHM-strain): Studies in vivo and in vitro. *Glia* **2**, 85–93.
- Vass, K., Lassmann, H., Wekerle, H., and Wisniosk, H. M. (1986). The distribution of Ia antigen in the lesions of rat acute experimental allergic encephalomyelitis. *Acta Neuropathol. (Berlin)* **70**, 149–160.
- Wang, F., Stohman, S. A., and Fleming, J. O. (1990). Demyelination induced by murine hepatitis virus JHM strain (MHV-4) is immunologically mediated. *J. Neuroimmunol.* **30**, 31–41.
- Weiner, L. P. (1973). Pathogenesis of demyelination induced by a mouse hepatitis virus (JHM virus). *Arch. Neurol.* **28**, 298–303.
- Yamaguchi, K., Goto, N., Kyuwa, S., Hayami, M., and Toyoda, Y. (1991). Protection of mice from a lethal coronavirus infection in the central nervous system by adoptive transfer of virus-specific T cell clones. *J. Neuroimmunol.* **32**, 1–9.
- Yong, V. W., and Antel, J. P. (1992). Major histocompatibility complex molecules on glial cells. *Semin. Neurosci.* **4**, 231–240.
- Zheng, Y., Schafer, M., Weihe, E., Sheng, H., Corisdeo, S., Fu, Z. F., Koprowski, H., and Dietzschold, B. (1993). Severity of neurological signs and degree of inflammatory lesions in the brains of rats with Borna disease correlate with the induction of nitric oxide synthase. *J. Virol.* **67**, 5786–5791.