



Contents lists available at ScienceDirect

## International Journal of Antimicrobial Agents

journal homepage: <http://www.elsevier.com/locate/ijantimicag>

# Virological and serological analysis of a recent Middle East respiratory syndrome coronavirus infection case on a triple combination antiviral regimen

Q1 Nicholas Spanakis<sup>a,1</sup>, Sotirios Tsiodras<sup>b,c,1</sup>, Bart L. Haagmans<sup>d</sup>, V. Stalin Raj<sup>d</sup>, Kostantinos Pontikis<sup>e</sup>, Antonia Koutsoukou<sup>e</sup>, Nikos Koulouris<sup>e</sup>, Albert D.M.E. Osterhaus<sup>d</sup>, Marion P.G. Koopmans<sup>d</sup>, Athanassios Tsakris<sup>a,\*</sup>

<sup>a</sup> Department of Microbiology, University of Athens Medical School, 75 Mikras Asias Street, 115 27 Athens, Greece

<sup>b</sup> Hellenic Centre for Disease Control and Prevention, Athens, Greece

<sup>c</sup> Department of Internal Medicine, University of Athens Medical School, Athens, Greece

<sup>d</sup> Department of Viroscience, Erasmus Medical Center, Rotterdam, The Netherlands

Q2 <sup>e</sup> First Department of Respiratory Medicine, University of Athens Medical School and 'Sotiria' Chest Diseases Hospital, Athens, Greece

## ARTICLE INFO

### Article history:

Received 25 July 2014

Accepted 28 July 2014

### Keywords:

MERS-CoV

MERS

Serology

Coronavirus

Antiviral treatment

Phylogeny

## ABSTRACT

Serological, molecular and phylogenetic analyses of a recently imported case of Middle East respiratory syndrome coronavirus (MERS-CoV) in Greece are reported. Although MERS-CoV remained detectable in the respiratory tract secretions of the patient until the fourth week of illness, viraemia was last detected 2 days after initiation of triple combination therapy with pegylated interferon, ribavirin and lopinavir/ritonavir, administered from Day 13 of illness. Phylogenetic analysis of the virus showed close similarity with other human MERS-CoVs from the recent Jeddah outbreak in Saudi Arabia. Immunoglobulin G (IgG) titres peaked 3 weeks after the onset of illness, whilst IgM levels remained constantly elevated during the follow-up period (second to fifth week of illness). Serological testing confirmed by virus neutralisation assay detected an additional case that was a close contact of the patient.

© 2014 Published by Elsevier B.V.

## 1. Introduction

An upsurge of Middle East respiratory syndrome coronavirus (MERS-CoV) infection has been recently described in countries of the Arabian Peninsula resulting in exported cases from these countries to the European Union [1]. Cases of MERS-CoV infection are associated with a high case fatality rate since there is no available treatment. There is a scarcity of data on specific therapeutic interventions for the disease. Published reports propose the use of known antivirals based on extrapolation of data from: (i) the severe acute respiratory syndrome (SARS) epidemic that was also associated with the circulation of a novel coronavirus; (ii) *in vitro* data; (iii) animal experimental infections and therapy data; and (iv) limited clinical data for actual MERS-CoV infections [2–4]. However, no clear-cut recommended therapeutic regimen exists and the evidence for grading such interventions is generally low, with

the exception of the use of convalescent serum that based on biological effects is given the highest grade [5]. Moreover, little is known about the viral kinetics of MERS-CoV-associated infection, especially when a specific antiviral or other therapeutic intervention is attempted.

A case of MERS-CoV has recently been described in Greece in a traveller who had extensive contact with the healthcare environment in Jeddah (Saudi Arabia) [6]. Here we describe molecular, serological and phylogenetic analyses of this case as well as evidence for a second case that was a close contact of the first patient. Furthermore, we provide evidence of the kinetics and the pattern of viral excretion in biological specimens obtained from the first Greek case while the patient was on a triple antiviral regimen.

## 2. Methods

### 2.1. Case investigation

A preliminary report of the first imported, laboratory-confirmed MERS-CoV case in Greece has been described elsewhere [6]. A full description of the course of illness and treatment regimen in

\* Corresponding author. Tel.: +30 210 746 2011; fax: +30 210 746 2210.

E-mail address: [atsakris@med.uoa.gr](mailto:atsakris@med.uoa.gr) (A. Tsakris).

<sup>1</sup> These two authors contributed equally to this work.

relation to kinetics of virus shedding and immune response was prepared by review of the patient records. In the course of the outbreak investigation, 40 of 75 patient's contacts, including the patient's wife, provided an oropharyngeal sample for PCR testing 1 week after contact with the positive case; 5 additional contacts were included in the serology examination group. All were submitted to personal clinical monitoring for fever and upper respiratory infection symptoms and were advised to call the Hellenic Centre for Disease Control and Prevention (CDC) command centre immediately in such an instance. In addition, all were offered the chance to provide serum samples on a voluntary basis for specific anti-MERS antibody testing at baseline (same time as the oropharyngeal PCR testing) and 3 weeks after exposure.

## 2.2. Laboratory evaluation

During the patient's stay in the intensive care unit (ICU), samples from the oropharynx, trachea, urine and faeces were tested for diagnostic evaluation and to monitor viral shedding. A real-time reverse transcription PCR (RT-PCR) method based on amplification of the upstream Envelope gene (*upE*), the nucleocapsid (N) gene and the open reading frame (ORF) 1a of the virus was used for detection of MERS-CoV according to previously described methodology [7,8].

Immunoglobulin G (IgG) and IgM antibody titres in serum samples were determined using an anti-MERS-CoV Indirect Immunofluorescence Assay (Euroimmun AG, Lübeck, Germany). Confirmation of the serological findings was performed with a virus neutralisation assay as described previously [9].

Samples from the patient's upper respiratory tract underwent conventional or molecular testing for the presence of other respiratory pathogens: thus, cultures applied for bacterial testing, whilst real-time RT-PCR was performed for several respiratory viruses including influenza A and B virus, respiratory syncytial virus (RSV), parainfluenza, adenovirus, enterovirus, bocavirus and human metapneumovirus (hMPV) (M.W.S. r-gene; bioMérieux, Marcy-l'Étoile, France). Specific urine antigen testing of urine samples was utilised for *Legionella pneumophila* and *Streptococcus pneumoniae* (BinaxNOW®; Alere, Orlando, FL). A stool culture was performed due to a history of possible typhoid fever, diagnosed by treating physicians in Saudi Arabia [6].

## 2.3. Phylogenetic analysis

Nucleotide sequences of 3-kb concatenated sequences of representative MERS-CoVs were analysed and a phylogenetic tree was constructed by the PhyML method as described previously [10].

## 3. Results

### 3.1. Case description

A 69-year-old patient of Greek origin who was a permanent resident of Jeddah presented to a tertiary care centre a few hours after arriving in Athens (Greece) on 17 April 2014. His chief complaints included fever since 8 April 2014 and diarrhoea since 10 April 2014. The most likely source of exposure was the hospital environment in Jeddah. The patient had no known co-morbidities. At the time of initial evaluation, a fever of 38.3 °C was noted together with low oxygen saturation (92%), although the patient exhibited minimal respiratory symptoms. A chest radiograph depicted bilateral lung infiltrates consistent with viral pneumonia. The patient was immediately placed under isolation because of suspicion of MERS-CoV infection, and an antimicrobial regimen targeting community-acquired pneumonia was initiated.

On 18 April 2014, MERS-CoV infection was confirmed by means of viral RNA detection in a pharyngeal swab at the Department

of Microbiology, University of Athens Medical School (Athens, Greece).

After laboratory confirmation of MERS-CoV, the patient was transferred to a specialised respiratory disease unit in the 'Sotiria' Chest Diseases Hospital of Athens where he was treated in a negative pressure regular room in isolation until 20 April 2014 when, due to deterioration of his respiratory function and development of acute respiratory disease syndrome (ARDS), he was intubated, ventilated and transferred to a negative pressure room in the ICU of the same hospital. An empirical antiviral regimen was initiated on Day 13 of illness consisting of oral (p.o.) lopinavir/ritonavir (400/100 mg twice daily), pegylated interferon (180 µg subcutaneously once per week for 12 days) and ribavirin (2000 mg p.o. loading dose, followed by 1200 mg p.o. every 8 h for 8 days) based on available evidence [3–5,11,12] (Fig. 1).

The patient remained intubated exhibiting hypoxia and occasionally hypercapnia while breathing inspired oxygen in the range of 0.45–0.60. He remained febrile with a plateau temperature of >39 °C and a maximum value of 40.5 °C on Day 18 of illness. Fever started subsiding below 38 °C on Day 22. Acute kidney injury was diagnosed on Day 16 of illness and rapidly progressed to non-oliguric renal failure that reverted to RIFLE injury level (i.e. two-fold increase in the serum creatinine, or glomerular filtration rate decrease by 50%, or urine output <0.5 mL/kg/h for 12 h) on Day 21. The patient's diarrhoea resolved gradually starting on Day 13 and he developed constipation thereafter with normalisation of his bowel movements and gastrointestinal function on Day 19. Owing to development of jaundice and hyperbilirubinaemia attributed to ribavirin [13], the drug was discontinued on Day 20. During the course of his hospitalisation, the patient was diagnosed with adenocarcinoma of the colon and eventually died from septic shock 2 months and 19 days after the initial diagnosis.

### 3.2. Testing for other pathogens

Cultures and antigen detection were negative for *L. pneumophila* and *S. pneumoniae*. Virological testing was negative for the presence of any other respiratory virus. No relevant enteric pathogens were identified as a cause of the patient's diarrhoea.

### 3.3. MERS-CoV testing and shedding

RNA was detected in several consecutive patient samples from different sites that included faecal material and serum (Fig. 1). Shedding of MERS-CoV in the respiratory secretions of the patient was noted until the fourth week of illness, whereas viraemia was last detected 15 days after onset of illness and 2 days after initiation of the triple combination antiviral regimen. Consecutive urine testing did not reveal the presence of MERS-CoV RNA (Fig. 1).

### 3.4. Serological testing for MERS-CoV and new possible case

Serological testing showed a peak IgG titre during the third week of illness, whilst during the fourth and fifth week IgG titres were substantially declining. IgM titres were persistently elevated during the whole survey period (Day 13 until Day 34 of illness) (Fig. 1). Viral neutralisation assays performed at Erasmus Medical Center (Rotterdam, The Netherlands) confirmed the immunofluorescence testing results.

Initial and follow-up serological testing was performed on serum samples from 45 patient's contacts. Seroconversion was revealed in one of them who developed an IgG titre of 1/500 and an IgM titre of 1/100 at 21 days after making contact with the patient. This was a 63-year-old man with a past medical history of coronary artery heart disease and diabetes. The presence of specific

DAY OF ILLNESS		0	1	2	3	4	5	6	7	8	9	10	11	12	13	14	15	16	17	18	19	20	21	22	23	24	25	26	27	28	29	30	31	32	33	34	35	36	37		
DATE (APRIL - MAY)		8	9	10	11	12	13	14	15	16	17	18	19	20	21	22	23	24	25	26	27	28	29	30	1	2	3	4	5	6	7	8	9	10	11	12	13	14	15		
Clinical signs	Fever (>38° C)																																								
	Respiratory Failure/Intubation																																								
	Diarrhea																																								
	Kidney failure																																								
Medication	Interferon																																								
	Ribavirin																																								
	Lopinavir/Ritonavir																																								
sReal Time PCR (UpE/N/Orf1a)	Pharyngeal or endotracheal aspirate																																								
	Faeces or Rectum swab																																								
	Serum or Whole blood																																								
	Urine																																								
Serology by IIF	IgM (positive above 1/10)																																								
	IgG (positive above 1/100)																																								
	IgG (positive above 1/1000)																																								

\*: Fever < 38° C, #: RIFLE level injury, NA: Not Available, \$: all methods returned the same qualitative result, Ct's from UpE method are used. ■: Presence of clinical sign

Fig. 1. Time course of symptoms, medication, and molecular and serological findings of the Middle East respiratory syndrome coronavirus (MERS-CoV)-infected patient. IIF, indirect immunofluorescence.

MERS-CoV antibodies was confirmed by the virus neutralisation assay.

3.5. Case investigation of the new case

Case investigation disclosed that the person who seroconverted had close contact with the first MERS-CoV case diagnosed in Greece on 18 April 2014. He had close contact with the index case for ca. 3 h and drove the index patient to the hospital on 17 April 2014. He had been identified as a close contact during the contact tracing conducted by the Hellenic CDC at the time and he was submitted to the following testing according to the protocol used for the investigation of close contacts by the Hellenic CDC: (i) nasopharyngeal testing (by PCR) on 23 April 2014 (negative); (ii) serology testing on 23 April 2014 (negative); and (iii) serology testing on 8 May 2014 (positive). The patient reported developing only fever (up to 38.5 °C) from 4 to 7 May 2014 without other symptoms from any other system. No nasopharyngeal PCR testing was performed at the time since he was outside the incubation period of 14 days. He has been well since then and during the time that he was symptomatic he only had contact with his family members (four persons). The initial patient's wife had a brief episode of fever on 30 May 2014. Oropharyngeal PCR testing was negative for MERS-CoV, and all contacts remained seronegative on repeat testing.

3.6. Phylogenetic results

Partial genomic sequencing [14] revealed the close phylogenetic relationship with clinical MERS-CoV strains associated with severe respiratory infection from patients in Jeddah (Fig. 2).

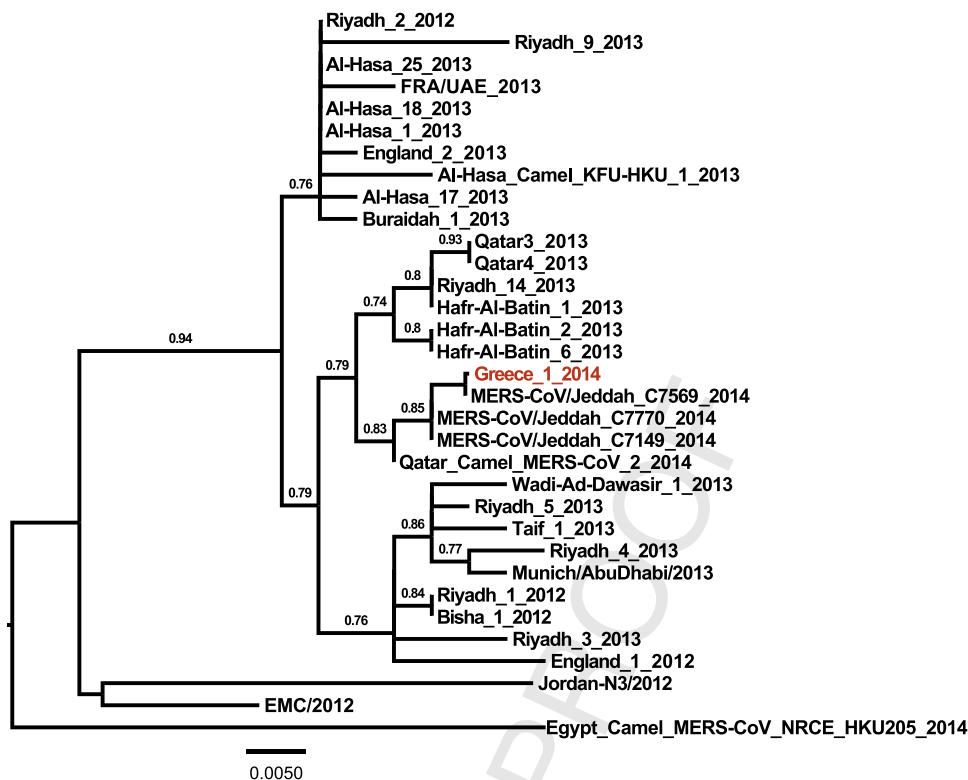
4. Discussion

In this report, we further characterised serological and virological parameters of the first MERS-CoV case in Greece. Rising titres of IgG were demonstrated in sequential serum samples, with the peak titres approximately 3 weeks into the course of the disease. This is in accordance with serological testing guidance from the World Health Organization (WHO) recommending baseline testing from initial contact with an affected case and repeated serological testing on Day 21 [15]. On the other hand, IgM titres of the patient remained constantly elevated above the threshold of detection, albeit at a lower level than IgG antibodies, for a prolonged period of ≥1 month of follow-up. Thus, isolated use of IgM testing without concomitant IgG determination appears not to be sufficient to reveal a recent infection. It should be noted, however, that in the

absence of detailed studies, use of serological testing for MERS-CoV detection in humans needs to be further evaluated.

Prolonged shedding of the virus was noted from the respiratory tract of the patient. This finding is consistent with data regarding the SARS coronavirus. In a report dealing with patients affected by SARS, prolonged shedding of the virus was noted in stool (up to 126 days) and respiratory specimens (up to 52 days) [16]. Data regarding the length of MERS-CoV excretion from different body sites are scarce [17]. Excretion of the virus probably depends on the amplitude of replication in different body sites, the underlying immune status and co-morbidities, and appropriate antiviral therapy. The non-detectable viral RNA in serum by Day 3 after initiation of the antiviral treatment could be explained either by viral clearance in an otherwise immunocompetent person or by effectiveness of the instituted antiviral regimen. Literature on appropriate antiviral intervention for MERS-CoV is very limited and currently no evidence-based therapy exists. The regimen chosen was based on the best available literature as well as evidence from animal and patient data that have been described elsewhere [2-4]. The role of interferon therapy for MERS-CoV infection needs to be further elucidated. An attenuated interferon-β (IFN-β) response has been described as a result of MERS-CoV infection [18] and extensive use of interferon-based regimens alone or in combination with ribavirin has been described for SARS [4]. However, interferons appear to have a better antiviral effect on MERS-CoV compared with SARS-CoV in in vitro experiments [19]. In vitro, IFN-β appears to exhibit the best anti-MERS-CoV effect [20]. Interferon activity has been enhanced by the addition of ribavirin in in vitro experiments [21]. Furthermore, this combination has shown promising clinical and radiological effects in Rhesus macaques experimentally infected with MERS-CoV [12]. Thus, the clinical team elected to use this combination despite the fact that a prestigious public health agency ranks ribavirin use as not supported by high-quality evidence [5]. In a more recent update published by the same public health agency, the use of interferons and lopinavir is ranked under the recommendation of benefit is likely to exceed risk, whereas the combination of interferon and ribavirin is ranked as data is inadequate for assessment [22]. The frequent side effects of ribavirin limit its use in combination regimens for actual MERS-CoV-infected patients, as was the experience with the current patient where liver toxicity, although not definitively associated, was mainly attributed to this medication. The renal function deterioration of the patient described here was considered multifactorial and probably also a complication of the virus infection [23]. The possibility that drug toxicity might have contributed in the renal dysfunction could not be excluded, however. No drug levels were measured since the

Please cite this article in press as: Spanakis N, et al. Virological and serological analysis of a recent Middle East respiratory syndrome coronavirus infection case on a triple combination antiviral regimen. Int J Antimicrob Agents (2014), <http://dx.doi.org/10.1016/j.ijantimicag.2014.07.026>



**Fig. 2.** Phylogenetic tree of the Middle East respiratory syndrome coronavirus (MERS-CoV) from the Greek patient. Nucleotide sequences of 3-kb concatenated sequences of representative MERS-CoVs were analysed and a phylogenetic tree was constructed by the PhyML method. Values at the branches show the result of the approximate likelihood ratio, with values of <0.70 not depicted.

264 patient was under continuous renal replacement therapy at that  
 265 time and drug levels would be unreliable. In the actual clinical  
 266 human setting, the combination of ribavirin and interferon has  
 267 been tried, with no successful outcome reported among any of the  
 268 MERS-CoV-infected recipients [3]. Nevertheless, the group studied  
 269 consisted of severely ill patients who received this combination  
 270 quite late in the course of their disease [3]. Lastly, we added the  
 271 protease inhibitors lopinavir/ritonavir based on experience accu-  
 272 mulated from the SARS epidemic where the addition of this agent  
 273 to ribavirin improved the outcome of infection [24].

274 Expanding the knowledge regarding viral kinetics and the pat-  
 275 tern of shedding especially in association with specific therapeutic  
 276 interventions has important implications for infection control in  
 277 the healthcare environment, especially as it relates to potential  
 278 transmission to other patients and healthcare workers [25].

279 Phylogenetic analysis of the Greek MERS-CoV strain showed  
 280 close similarity with circulating patient viral strains from the  
 281 recent Jeddah outbreak as well as with a strain isolated from a  
 282 dromedary camel in Qatar. This is in accordance with previous  
 283 genetic studies that have shown identical viral strains between  
 284 infected humans and dromedary camels and generated the hypoth-  
 285 esis that dromedary camels are among the reservoirs of the virus  
 286 in nature [10,26]. Also, the presence of MERS-CoV-specific anti-  
 287 bodies in camels across a wide geographic area in Africa and the  
 288 Arabian Peninsula signifies the possibility for zoonotic transmission  
 289 between camels and humans [27–29]. The potential for transmis-  
 290 sion across different individual strains should be further explored.  
 291 In this patient, the most likely source of exposure was the hospital  
 292 environment in an endemic area, as his wife was hospitalised in  
 293 a local hospital in Jeddah [6]. It appears that healthcare-associated  
 294 outbreaks are playing a pivotal role in the evolution of the MERS-  
 295 CoV epidemic in the recent upsurge [30].

296 **5. Conclusions**

297 In conclusion, we describe the genetic stability of the MERS-CoV  
 298 in a strain from the recent Jeddah outbreak. Although reassuring,  
 299 this finding should not limit the level of awareness regarding the  
 300 increased number of cases in the Arabian Peninsula reported  
 301 recently and the potential evolution and more efficient transmis-  
 302 sion of the virus. A WHO committee recently concluded that the  
 303 conditions for a Public Health Emergency of International Concern  
 304 have not yet been met. Nevertheless, important gaps in current  
 305 knowledge about MERS-CoV exist. More investigations to clarify  
 306 the natural reservoir and modes of transmission are necessary. Per-  
 307 sistence of virus shedding in patients' secretions and the effect of  
 308 immune status and antiviral therapy together with the implemen-  
 309 tation of appropriate infection control measures are of paramount  
 310 importance in limiting further spread of this potentially lethal virus.

311 **Acknowledgments**

312 The authors would like to acknowledge the Department of Epi-  
 313 demiological Surveillance and Response of the Hellenic Centre for  
 314 Disease Control and Prevention (CDC), and especially Dr Georgia  
 315 Spala, Theano Georgakopoulou and Agoritsa Baka, for MERS-related  
 316 activities, as well as Dr Spyros Sapounas for contacting the case  
 317 investigation of the second case.

318 **Funding**

319 This work was funded by a grant from The Netherlands Organi-  
 320 sation for Scientific Research (NWO) [no. 40-00812-98-13066].

**Competing interests**

None declared.

**Ethical approval**

Not required.

**References**

- [1] European Centre for Disease Prevention and Control. Epidemiological update: Middle East respiratory syndrome coronavirus (MERS-CoV). ECDC; 2 July 2014. [http://www.ecdc.europa.eu/en/press/news/\\_layouts/forms/News.DispForm.aspx?List=8db7286c-fe2d-476c-9133-18ff4cb1b568&ID=1029](http://www.ecdc.europa.eu/en/press/news/_layouts/forms/News.DispForm.aspx?List=8db7286c-fe2d-476c-9133-18ff4cb1b568&ID=1029) [accessed 9 September 2014].
- [2] Al-Tawfiq JA, Memish ZA. What are our pharmacotherapeutic options for MERS-CoV? *Expert Rev Clin Pharmacol* 2014;7:235–8.
- [3] Al-Tawfiq JA, Momattin H, Dib J, Memish ZA. Ribavirin and interferon therapy in patients infected with the Middle East respiratory syndrome coronavirus: an observational study. *Int J Infect Dis* 2014;20:42–6.
- [4] Momattin H, Mohammed K, Zumla A, Memish ZA, Al-Tawfiq JA. Therapeutic options for Middle East respiratory syndrome coronavirus (MERS-CoV)—possible lessons from a systematic review of SARS-CoV therapy. *Int J Infect Dis* 2013;17:e792–8.
- [5] Clinical Decision Making Tool for Treatment of MERS-CoV v.1.1, 29 July, 2013. Public Health England. [http://webarchive.nationalarchives.gov.uk/20140714084352/http://www.hpa.org.uk/webc/HPAwebFile/HPAweb\\_C/1317139281416](http://webarchive.nationalarchives.gov.uk/20140714084352/http://www.hpa.org.uk/webc/HPAwebFile/HPAweb_C/1317139281416) [accessed 11 September 2014].
- [6] Tsiodras S, Baka A, Mentis A, Iliopoulos D, Dedoukou X, Papamavrou G, et al. A case of imported Middle East respiratory syndrome coronavirus infection and public health response, Greece, April 2014. *Euro Surveill* 2014;19:20782.
- [7] Corman VM, Müller MA, Costabel U, Timm J, Binger T, Meyer B, et al. Assays for laboratory confirmation of novel human coronavirus (hCoV-EMC) infections. *Euro Surveill* 2012;17, pii: 20334.
- [8] Corman VM, Eckerle I, Bleicker T, Zaki A, Landt O, Eschbach-Bludau M, et al. Detection of a novel human coronavirus by real-time reverse-transcription polymerase chain reaction. *Euro Surveill* 2012;17, pii: 20285.
- [9] Reusken CB, Haagmans BL, Müller MA, Gutierrez C, Godeke GJ, Meyer B, et al. Middle East respiratory syndrome coronavirus neutralising serum antibodies in dromedary camels: a comparative serological study. *Lancet Infect Dis* 2013;13:859–66.
- [10] Haagmans BL, Al Dhahiry SH, Reusken CB, Raj VS, Galiano M, Myers R, et al. Middle East respiratory syndrome coronavirus in dromedary camels: an outbreak investigation. *Lancet Infect Dis* 2014;14:140–5.
- [11] Khalid M, Al Rabiah F, Khan B, Al Mobeireek A, Butt TS, Mutairy E, et al. Ribavirin and interferon (IFN)- $\alpha$ -2b as primary and preventive treatment for Middle East respiratory syndrome coronavirus (MERS-CoV): a preliminary report of two cases. *Antivir Ther* 2014. <http://dx.doi.org/10.3851/IMP2792> [Epub ahead of print].
- [12] Falzarano D, de Wit E, Rasmussen AL, Feldmann F, Okumura A, Scott DP, et al. Treatment with interferon- $\alpha$ 2b and ribavirin improves outcome in MERS-CoV-infected rhesus macaques. *Nat Med* 2013;19:1313–7.
- [13] Schering Corp Product information. REBETOL® (ribavirin, USP). Kenilworth, NJ: Schering Corp. <http://archives.who.int/eml/expcom/expcom15/applications/newmed/ribaravin/APP.REBETOL.pdf> [accessed 9 September 2014].
- [14] Raj VS, Farag EA, Reusken CB, Lamers MM, Pas SD, Voermans J, et al. Isolation of MERS coronavirus from dromedary camel, Qatar, 2014. *Emerg Infect Dis* 2014;20:1339–42.
- [15] World Health Organization Seroepidemiological investigation of contacts of Middle East respiratory syndrome coronavirus (MERS-CoV) patients. Geneva: Switzerland: WHO; 19 November 2013. [http://www.who.int/csr/disease/coronavirus\\_infections/WHO\\_Contact\\_Protocol\\_MERSCoV\\_19\\_November\\_2013.pdf?ua=1](http://www.who.int/csr/disease/coronavirus_infections/WHO_Contact_Protocol_MERSCoV_19_November_2013.pdf?ua=1) [accessed 9 September 2014].
- [16] Liu W, Tang F, Fontanet A, Zhan L, Zhao QM, Zhang PH, et al. Long-term SARS coronavirus excretion from patient cohort, China. *Emerg Infect Dis* 2004;10:1841–3.
- [17] Arabi YM, Arifi AA, Balkhy HH, Najm H, Aldawood AS, Ghabashi A, et al. Clinical course and outcomes of critically ill patients with Middle East respiratory syndrome coronavirus infection. *Ann Intern Med* 2014;160:389–97.
- [18] Lau SK, Lau CC, Chan KH, Li CP, Chen H, Jin DY, et al. Delayed induction of proinflammatory cytokines and suppression of innate antiviral response by the novel Middle East respiratory syndrome coronavirus: implications for pathogenesis and treatment. *J Gen Virol* 2013;94:2679–90.
- [19] Kindler E, Jónsdóttir HR, Muth D, Hamming OJ, Hartmann R, Rodriguez R, et al. Efficient replication of the novel human betacoronavirus EMC on primary human epithelium highlights its zoonotic potential. *MBio* 2013;4:e00611–612.
- [20] Hart BJ, Dyall J, Postnikova E, Zhou H, Kindrachuk J, Johnson RF, et al. Interferon- $\beta$  and mycophenolic acid are potent inhibitors of Middle East respiratory syndrome coronavirus in cell-based assays. *J Gen Virol* 2014;95:571–7.
- [21] Falzarano D, de Wit E, Martellaro C, Callison J, Munster VJ, Feldmann H. Inhibition of novel  $\beta$  coronavirus replication by a combination of interferon- $\alpha$ 2b and ribavirin. *Sci Rep* 2013;3:1686.
- [22] PHE update on MERS-CoV. Public Health England; 14 May 2014. <https://www.gov.uk/government/news/phe-update-on-mers-cov> [accessed 11 September 2014].
- [23] Eckerle I, Muller MA, Kallies S, Gotthardt DN, Drosten C. In-vitro renal epithelial cell infection reveals a viral kidney tropism as a potential mechanism for acute renal failure during Middle East respiratory syndrome (MERS) coronavirus infection. *Virology* 2013;10:359.
- [24] Chu CM, Cheng VC, Hung IF, Wong MM, Chan KH, Chan KS, et al. Role of lopinavir/ritonavir in the treatment of SARS: initial virological and clinical findings. *Thorax* 2004;59:252–6.
- [25] Assiri A, McGeer A, Perl TM, Price CS, Al Rabeeah AA, Cummings DA, et al. Hospital outbreak of Middle East respiratory syndrome coronavirus. *N Engl J Med* 2013;369:407–16.
- [26] Briese T, Mishra N, Jain K, Zalmout IS, Jabado OJ, Karesh WB, et al. Middle East respiratory syndrome coronavirus quasispecies that include homologues of human isolates revealed through whole-genome analysis and virus cultured from dromedary camels in Saudi Arabia. *MBio* 2014;5:e01146–1214.
- [27] Reusken CB, Messadi L, Feyisa A, Ularanu H, Godeke GJ, Danmarwa A, et al. Geographic distribution of MERS coronavirus among dromedary camels, Africa. *Emerg Infect Dis* 2014;20:1370–4.
- [28] Hemida MG, Perera RA, Wang P, Alhammadi MA, Siu LY, Li M, et al. Middle East respiratory syndrome (MERS) coronavirus seroprevalence in domestic livestock in Saudi Arabia, 2010 to 2013. *Euro Surveill* 2013;18:20659.
- [29] Reusken CB, Ababneh M, Raj VS, Meyer B, Eljarah A, Abutarbush S, et al. Middle East respiratory syndrome coronavirus (MERS-CoV) serology in major livestock species in an affected region in Jordan, June to September 2013. *Euro Surveill* 2013;18:20662.
- [30] World Health Organization Middle East respiratory syndrome coronavirus (MERS-CoV) summary and literature update—as of 9 May 2014. [http://www.who.int/csr/disease/coronavirus\\_infections/MERS.CoV\\_Update.09\\_May.2014.pdf?ua=1](http://www.who.int/csr/disease/coronavirus_infections/MERS.CoV_Update.09_May.2014.pdf?ua=1) [accessed 14 May 2014].