

Outbreak of Middle East Respiratory Syndrome-Coronavirus Causes High Fatality After Cardiac Operations



Rakan I. Nazer, MD

Department of Cardiac Science, King Fahad Cardiac Center, College of Medicine, King Saud University, Riyadh, Kingdom of Saudi Arabia

Middle East respiratory syndrome-coronavirus (MERS-CoV) resembles a severe form of community-acquired pneumonia initially reported in Saudi Arabia in 2012. The MERS-CoV epidemic poses a big challenge because of its high mortality. In January 2015, a patient who was potentially incubating MERS-CoV arrived from the emergency department of another hospital and was admitted with acute coronary syndrome. This resulted in an outbreak in the cardiac surgery ward that caused the deaths of 5 of 6 patients who had undergone cardiac operations.

(Ann Thorac Surg 2017;104:e127-9)

© 2017 by The Society of Thoracic Surgeons

The coronavirus belongs to a single-strand RNA family of viruses that are known to cause upper respiratory tract infection in humans [1]. In June 2012, a 60-year-old businessman presented with fever, cough, respiratory and renal failure in Saudi Arabia. He eventually died, and the agent responsible for this severe form of community-acquired pneumonia was identified as a novel beta coronavirus isolated from endotracheal aspiration [2]. Subsequently, the virus was renamed Middle East respiratory syndrome-coronavirus (MERS-CoV) (Fig 1). According to the World Health Organization's MERS-CoV Global Summary and Risk Assessment published in December 2016, there have been 1,841 laboratory-confirmed cases of the virus in 27 countries, the majority of which (80% cases) have been reported in the Kingdom of Saudi Arabia [3]. Unlike the earlier pandemic of severe acute respiratory syndrome-COV caused by a similar coronavirus strain in 2002 to 2003, MERS-CoV has a higher case fatality rate (40% versus 10%) and is an ongoing pandemic worldwide [4]. This report describes a series of 6 patients who were admitted to the cardiac surgery ward at King Khalid University Hospital in Riyadh, Saudi Arabia between January and February 2015 and who contracted MERS-CoV infection from a post-coronary artery bypass (CABG) index case exposed to the virus in another hospital. Five of the 6 patients undergoing cardiac operations died (case fatality rate of 83%). This particular MERS-CoV outbreak lasted 2 months and

resulted in 23 confirmed cases, including 13 infections among local health care staff.

Case Reports

Case 1 (Index Case)

A hypertensive 41-year-old man who was a heavy smoker went to a community hospital in Riyadh after experiencing an acute coronary syndrome. The patient spent 2 days at the community hospital, which was known to harbor reported cases of MERS-CoV infections. He was later transferred to King Khalid University Hospital on January 27, 2015, where he was found to have triple-vessel coronary disease and was scheduled for urgent CABG. The patient had no respiratory symptoms, fever, or other signs of infection. His preoperative chest roentgenogram was clear. He underwent uncomplicated CABG and was transferred to the cardiac ward on the second postoperative day. On the fifth postoperative day, the patient started to experience fever, with respiratory failure and infiltrations seen on his chest roentgenogram. He quickly progressed to respiratory arrest on day 6 and required intubation and intensive care admission. The screening for MERS-CoV from nasopharyngeal swabs was positive. This was the first confirmed MERS-CoV infection at our hospital. He died 30 days later of sepsis and multiorgan failure.

Case 2

An 87-year-old man was known to have sick sinus syndrome and had a permanent pacemaker, atrial fibrillation, and heart failure. On February 1, 2015, the patient was electively admitted to the cardiac surgery ward for a permanent pacemaker pulse generator change. On the fifth day after his elective operation, the patient experienced fever with confusion. His chest roentgenogram showed infiltrations, and he tested positive for MERS-CoV. He died 25 days later of progressive respiratory failure.

Case 3

An 83-year-old man was admitted to a long-stay room in the cardiac surgery ward for 4 months after experiencing a subdural hematoma after aortic aneurysm repair. He was spontaneously breathing with a tracheal mask. On February 25, 2015, he experienced desaturation with bilateral chest infiltrations seen on a roentgenogram. He died the next day in intensive care from severe respiratory failure.

Case 4

A 54-year-old male smoker, who shared a common room with the index case before his operation, was admitted after having an acute coronary syndrome. He underwent

Accepted for publication Feb 22, 2017.

Address correspondence to Dr Nazer, 3642 King Saud University, Riyadh 12372-7143, Saudi Arabia; email: raknazer@ksu.edu.sa.

The Appendix can be viewed in the online version of this article [<http://dx.doi.org/10.1016/j.athoracsur.2017.02.072>] on <http://www.annalsthoracicsurgery.org>.

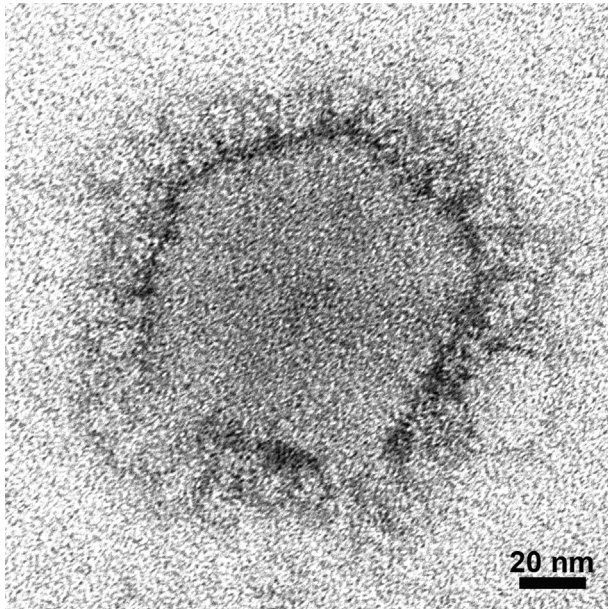


Fig 1. An electron microscopic image of Middle East respiratory syndrome-coronavirus (MERS-CoV) prepared by negative stain method with a micron bar. (Courtesy of C. Goldsmith and A. Tamin of the Centers for Disease Control and Prevention, Atlanta, GA).

CABG on February 22, 2015. He started to experience fever, loose stools, and cough on the fifth day after his operation. His chest roentgenogram did not show

infiltrations. He tested positive for MERS-CoV. He was kept in an isolation room and was successfully discharged home 8 days after exhibiting symptoms. He eventually made a full recovery on follow-up.

Case 5

A 52-year-old male nonsmoker with diabetes, who shared a common room with the index case before his operation, was admitted after having an acute coronary syndrome. He underwent CABG on February 15, 2015. He stayed in the intensive care unit for 10 days after his operation because of perioperative myocardial infarction. On the fifth day after transfer to a common room, he started to experience fever with desaturation and infiltrations on roentgenography. He tested positive for MERS-CoV. He died 7 days after exhibiting infection of severe respiratory failure.

Case 6

A 61-year-old patient who shared a common room with the fourth and fifth cases before operation (before the other patients had symptoms). He was admitted with acute coronary syndrome. He underwent CABG on February 26, 2015. He started to experience fever with hypoxia and infiltrations on chest roentgenography on the fifth day after the operation. He was found to be positive for MERS-CoV. He was intubated and died 7 days after exhibiting infection of severe respiratory failure.

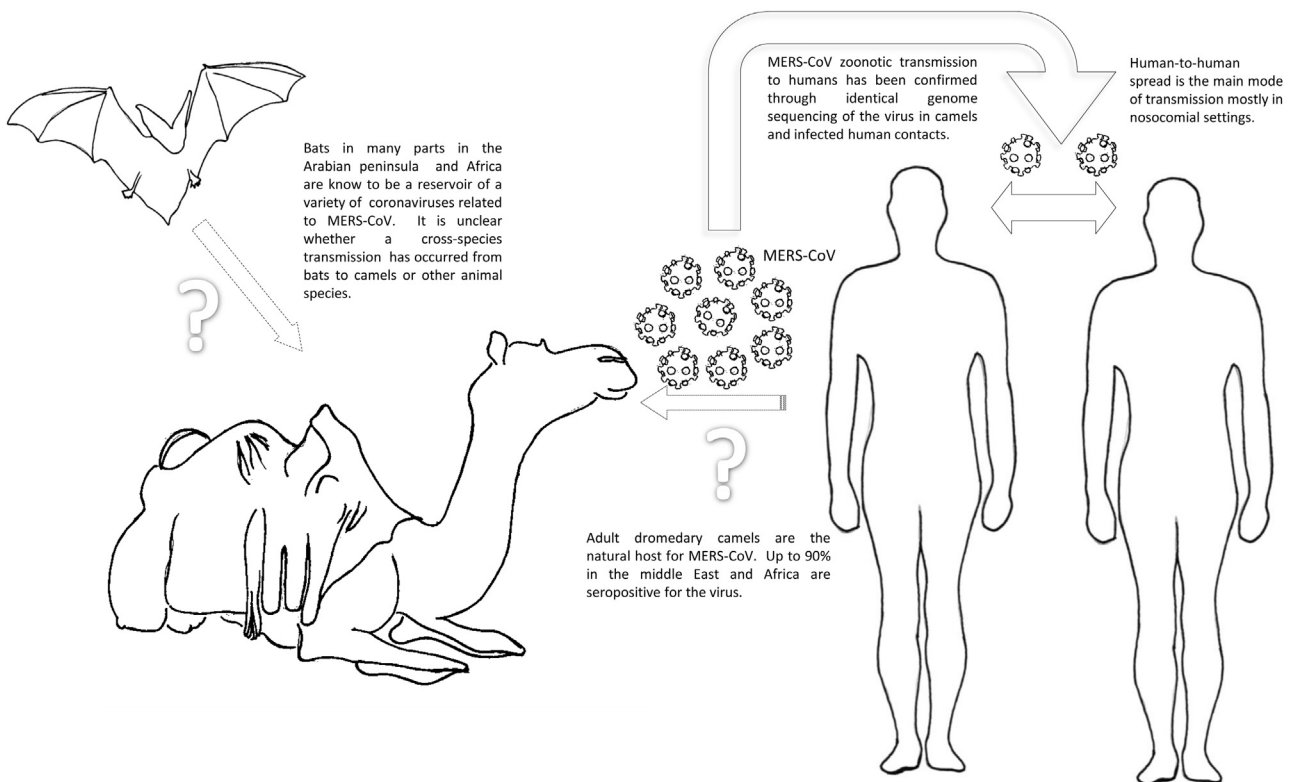


Fig 2. Current understanding of coronavirus transmission between animal and human species. (MERS-CoV = Middle East respiratory syndrome-coronavirus.)

Comment

MERS-CoV represents a big challenge for the health care system in the Kingdom of Saudi Arabia. According to the World Health Organization, Saudi Arabia has the highest reported number of laboratory-confirmed infections (1,496 confirmed cases), with a case fatality rate of 41.6% [3]. Serologic features point toward a zoonotic transmission from an animal reservoir to humans (Fig 2) [4]. Mounting evidence has identified dromedary (single-humped) camels as the natural host of MERS-CoV [5]. Although the route for camel-to-human transmission is not clear, human-to-human transmission through respiratory droplets, especially in hospital settings, has accounted for the majority of infections. The global case-fatality rate is estimated to be about 36%, with most fatalities occurring in elderly male patients with diabetes, heart and lung disease [5]. Like the initial severe acute respiratory syndrome-COV outbreaks in 2003 to 2004, the MERS-CoV nosocomial spread is primarily the result of the initial novelty of the virus and inadequate compliance with basic infection control protocols. This series strongly highlights the susceptibility of patients who undergo cardiac surgical procedures in a MERS-CoV outbreak situation. All patients were admitted into the same ward, and 5 of them shared a common room with other patients who were either incubating the virus (incubation time is 2–14 days) or had just started to exhibit respiratory symptoms. Most infected patients started to exhibit symptoms of fever, cough, and shortness of breath by the fifth day after operation. To date, treatment is largely supportive, with prudent initiation of protocols to prevent further spread of this highly contagious infection. This series was part of a hospital-wide outbreak that started in the cardiac surgery ward and spread to other departments in the hospital. Two additional patients died who were not in direct contact with the cardiac surgery ward or its staff.

Strict infection control measures have been implemented since this outbreak took place. Immediate actions included implementing a hospital-wide lockdown, screening health care staff who had contact with the infected patients, and establishing negative-pressure isolation rooms for infected patients or those suspected of being infected. For patients who need urgent CABG after exposure to MERS-CoV or show any symptoms of respiratory illness, percutaneous coronary intervention or postponing the operation should be considered. Permanent actions included ongoing health-care staff education on infection prevention measures, implementation of a respiratory illness scoring tool (Appendix) used for screening all patients admitted for urgent cardiac procedures, and establishing a cardiac stepdown unit as an intermediate-stay unit after intensive care discharge. This added to our better understanding of the pathogenesis of the MERS-CoV virus, and continued international collaborations have effectively halted further outbreaks since March 2015 until now.

This project was supported by College of Medicine Research Centre, Deanship of Scientific Research, King Saud University.

References

1. Alsolamy S. Middle East respiratory syndrome: knowledge to date. *Crit Care Med* 2015;43:1283–90.
2. Zaki AM, van Boheemen S, Bestebroer TM, Osterhaus AD, Fouchier RA. Isolation of a novel coronavirus from a man with pneumonia in Saudi Arabia. *N Engl J Med* 2012;367:1814–20.
3. World Health Organization. Middle East respiratory syndrome coronavirus (MERS-CoV). Available at: <http://www.who.int/emergencies/mers-cov/en/>.
4. de Wit E, van Doremalen N, Falzarano D, Munster VJ. SARS and MERS: recent insights into emerging coronaviruses. *Nat Rev Microbiol* 2016;14:523–34.
5. Arabi YM, Balkhy HH, Hayden FG, et al. Middle East respiratory syndrome. *N Engl J Med* 2017;376:584–94.