

## Pneumonia Caused by Coronavirus 229E and Parainfluenza 3 Coinfection in a Lung Transplant Recipient

### To the Editor:

Respiratory viruses are well-known causes of common colds and self-limiting upper respiratory infections in immunocompetent individuals. Conversely, in immunocompromised hosts, they are responsible for more severe manifestations associated with a significant morbidity and mortality. In lung transplant recipients, these pathogens have also been implicated in bronchiolitis syndrome and acute rejection.<sup>1</sup> Infection by 2 or more viruses is uncommon, but it has been reported increasingly in recent years because of the development of new molecular techniques. We present the case of a lung transplant recipient that developed pneumonia secondary to coronavirus 229E and parainfluenza (PIV) 3. To our knowledge, this is the first case reported in the literature.

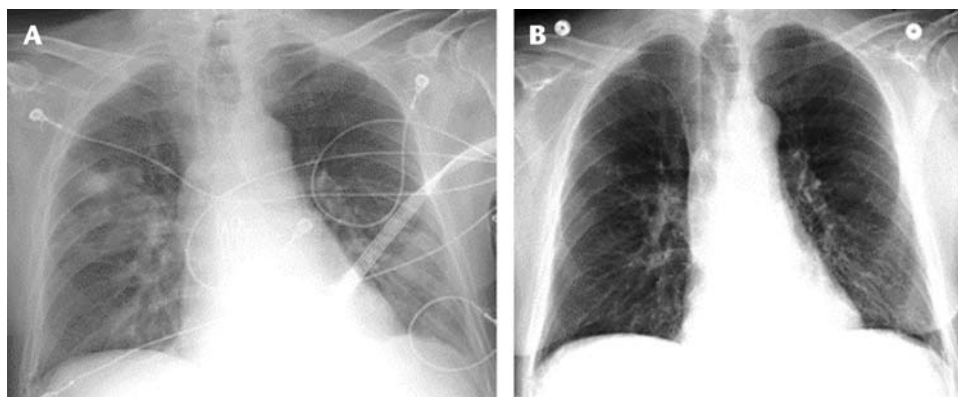
A 68-year-old man presents to the hospital with productive cough, fever, and chills over the past 2 days. His son had severe flu-like symptoms during the past week. His past medical history was significant for end-stage chronic obstructive pulmonary disease requiring double lung transplant in September 2016. He also suffered from hypertension and stroke with residual motor deficit. His antirejection regimen consisted of tacrolimus, mycophenolate mofetil, and prednisone. He was also taking valgancyclovir, voriconazole, and atovaquone as prophylaxis. On admission, his temperature was 37.9°C, pulse of 80 beats per minute, respiratory rate of 16 breaths per minute, and blood pressure of 147/80 mm Hg. His lung examination revealed decreased breath sounds in left lower lung and mild bibasilar crackles. No wheezing was noted. Laboratory studies showed normal white blood cell count (4.3 K/uL), low hemoglobin (9.1 g/dL), normal platelet count (188 k/uL), and elevated creatinine (1.24 mg/dL). Chest x-ray revealed multifocal patchy opacifications with a nodular density in the right upper lobe measuring 1.8 × 2.1 cm (Fig. 1A). To further evaluate the pulmonary involvement, a chest computed tomography was ordered, which demonstrated patchy nodular ground glass opacities throughout right lung, lingula, and left lower lobe. New nodules of 6 to 9 mm were also found in right middle and lower lobes. The

patient was started empirically on piperacillin/tazobactam and vancomycin. One day later, he underwent bronchoscopy, which showed purulent secretions in lower lobes. Bronchoalveolar lavage (BAL) specimen was sent for cultures. Respiratory panel polymerase chain reaction (FilmArray) from BAL identified coronavirus 229E and PIV 3. The patient improved significantly over the following days. Antibiotics were discontinued 3 days later when final cultures from BAL were reported as negative. At hospital day 6, chest x-ray was repeated and revealed near complete resolution of right upper lung opacities (Fig. 1B).

Human coronavirus (HCoV) and PIV have emerged as important pathogens responsible for lower respiratory tract infections especially in immunocompromised individuals. Human coronavirus is a positive-sense single-stranded RNA virus classified in 4 different genera. The HCoV 229E constitutes 1 of the 5 non-severe acute respiratory syndrome coronavirus serotypes associated with disease in humans. Although uncommon, this strain has been implicated as a cause of pneumonia in patients with hematologic malignancies and hematopoietic cell transplant recipients.<sup>2</sup> Additional cases of HCoV 229E pneumonia have been described in patients with HIV and asthma. In lung transplant recipients, HCoV has been found in 16% of patients that present with community acquired respiratory viral infections.<sup>3</sup>

Parainfluenza is a single-stranded RNA associated with a wide spectrum of respiratory illnesses, mainly upper respiratory infections in children. It has also been implicated in lower respiratory tract infections, bronchiolitis obliterans, and acute rejection among lung transplant recipients. According to some reports, it constitutes one of the leading causes of lower respiratory infections in the postlung transplant period.<sup>1</sup> The PIV 3 is the most prevalent serotype and is isolated mainly during spring and winter months. This strain can occasionally cause severe manifestations leading to respiratory failure with a mortality rate as high as 35%.

Pneumonia caused by viral coinfections has been reported uncommonly in transplant recipients. Only 2 cases has been documented in the literature, a case of PIV 4B and rhinovirus coinfection in a liver transplant recipient and a fatal case of human metapneumovirus and influenza B virus coinfection in a patient with bone marrow transplant.<sup>4,5</sup> The availability of new molecular techniques such as reverse polymerase chain reaction will certainly lead to the identification of more cases in the future; however, the clinical



**FIGURE 1.** A, Chest x-ray on admission showing patchy opacifications in right upper lobe. B, Chest x-ray at hospital day 6, showing near complete resolution of right upper lobe opacifications.

significance of these viral coinfections in vulnerable transplant recipients is still uncertain.

Our case highlights the importance of considering viral coinfections as a cause of pneumonia in lung transplant recipients. Further studies are needed to determine the clinical implications of these mixed viral infections in immunocompromised individuals.

**Jose Armando Gonzales Zamora, MD**

Division of Infectious Diseases  
Department of Medicine  
University of Miami  
Miller School of Medicine  
Miami, FL

*The author has no funding or conflicts of interest to disclose.*

## REFERENCES

1. Vu DL, Bridevaux PO, Aubert JD, et al. Respiratory viruses in lung transplant recipients: a critical review and pooled analysis of clinical studies. *Am J Transplant.* 2011;11(5):1071–1078.
2. Pene F, Merlat A, Vabret A, et al. Coronavirus 229E-related pneumonia in immunocompromised patients. *Clin Infect Dis.* 2003;37(7):929–932.
3. Gottlieb J, Schulz TF, Welte T, et al. Community-acquired respiratory viral infections in lung transplant recipients: a single season cohort study. *Transplantation.* 2009;87(10):1530–1537.
4. Sridhar S, Luk HK, Lau SK, et al. First report of severe parainfluenza virus 4B and rhinovirus C coinfection in a liver transplant recipient treated with immunoglobulin. *J Clin Virol.* 2014;61(4):611–614.
5. Ghattas C, Mossad SB. Fatal human metapneumovirus and influenza B virus coinfection in an allogeneic hematopoietic stem cell transplant recipient. *Transpl Infect Dis.* 2012;14(5):E41–E43.