



Clinical presentation, diagnostic findings, and outcome of adult horses with equine coronavirus infection at a veterinary teaching hospital: 33 cases (2012–2018)

E.H. Berryhill*, K.G. Magdesia, M. Aleman, N. Pusterla

Department of Medicine and Epidemiology, School of Veterinary Medicine, University of California, Davis, One Shields Ave., Davis, CA, 95616, USA

ARTICLE INFO

Keywords:

Colic
Diarrhea
Fever
Gastrointestinal
Infectious

ABSTRACT

Equine coronavirus (ECoV) is a recently described enteric virus with worldwide outbreaks; however, there are little data available on clinical presentation, diagnosis, and outcome. The study objective was to document case management of ECoV in adult horses presented to a referral hospital and compare to a cohort of horses that tested negative for ECoV. A retrospective case series was performed based on positive real-time quantitative PCR results for ECoV on faeces from horses treated at the UC Davis Veterinary Medical Teaching Hospital from 1 March 2012 to 31 March 2018. Horses negative for ECoV were matched to the ECoV-positive group as controls. Data collected included signalment, history, exam findings, diagnostics, treatment, and follow-up.

Thirty-three horses (median age, 11 years; range, 2–37 years) tested ECoV-positive, including three horses with co-infections. Presenting complaints for ECoV-infected horses included historic fevers ($n=25/30$; 83%), anorexia ($n=14/30$; 47%), and colic ($n=13/30$; 43%). ECoV-positive horses had significantly lower white blood cell (median, $3.0 \times 10^9/L$; range, $0.68\text{--}16.2 \times 10^9/L$), neutrophil (median, $1.26 \times 10^9/L$; range, $0.15\text{--}14.4 \times 10^9/L$), and lymphocyte (median, $0.86 \times 10^9/L$; range, $0.42\text{--}3.47 \times 10^9/L$) counts than ECoV-negative horses. Electrolyte and metabolic derangements and scant faeces were common. Twenty-seven horses were hospitalised for a median of 5 days (range, 0.5–14 days), with 26/27 (96%) horses surviving to discharge. ECoV infection should be a differential diagnosis for adult horses with fever, colic, anorexia, and leukopenia. The disease has a low mortality rate, but horses may require intensive care to resolve severe leukopenia, systemic inflammation, and metabolic disturbances.

© 2019 Elsevier Ltd. All rights reserved.

Introduction

Equine coronavirus (ECoV) is recognised as a cause of fever, anorexia, lethargy, leukopenia, and gastrointestinal disease in adult horses (Pusterla et al., 2018). Disease outbreaks have been reported in adult horses in boarding stables or competitive facilities across the United States, Europe, and Japan (Oue et al., 2013; Pusterla et al., 2013; Miszczak et al., 2014; Pusterla et al., 2018). The recent increase in positive cases likely reflects increased awareness of the virus, and increased availability and timeliness of testing through fecal real-time quantitative polymerase chain reaction (qPCR) (Pusterla et al., 2013).

Many cases of ECoV are self-limiting with transient clinical signs, however fatalities, endotoxemia and hyperammonemia can occur (Fielding et al., 2015). Miniature horses may be more susceptible to severe disease and had a higher fatality rate in an

outbreak (Fielding et al., 2015). In contrast, foals <1 year of age do not seem to be clinically affected as frequently as adult horses, and ECoV is often present as a co-infection with other gastrointestinal pathogens in foals (Slovio et al., 2014).

While data regarding ECoV epidemiology are available, there is a paucity of data on clinical presentation of cases, diagnosis, and outcome from a clinical perspective. The purpose of the current study was to document cases of ECoV diagnosed through fecal qPCR and presenting to a tertiary referral hospital.

Materials and methods

Study population

Records of adult horses >1 year of age, examined by a veterinarian at the UC Davis Veterinary Medical Teaching Hospital or on the ambulatory service between 1 March 2012 and 31 March 2018, and with faeces positive for ECoV by qPCR were obtained. Records of horses with negative fecal qPCR panels during the same time period were also obtained, and negative controls were selected by matching to ECoV-positive horses, prioritising first age, then time, and lastly sex. Horses had fecal qPCRs performed due to presence of fever, loose manure, or leukopenia as dictated by infectious disease protocol at the hospital, or due to signs of abdominal

* Corresponding author.

E-mail address: ehberryhill@vmth.ucdavis.edu (E.H. Berryhill).

discomfort in addition to any of the former criteria. Pathogens included in the fecal qPCR panel at the institution are ECoV, *Salmonella* spp., *Clostridium difficile* (toxin A and B), *Lawsonia intracellularis*, and *Neorickettsia risticii*. Fecal cultures for *Salmonella* spp. were also performed at the institution on every hospitalized horse. Respiratory qPCR panels are often performed as diagnostics for infectious disease screening, including testing for equine Influenza A virus, equine rhinitis A and B viruses, equine herpesvirus-1 and -4, and *Streptococcus equi* ssp. *equi*.

Data collected from records included signalment, presenting complaints, predisposing causes for infectious disease, physical examination and clinicopathological findings, hospitalisation and treatment, and follow-up. Clumped platelet counts were excluded from analysis. The last complete blood count (CBC) submitted for the visit in question was utilised for follow-up data.

PCR analysis

Nucleic acid extractions from faeces were performed using an automated nucleic acid extraction system (CAS-1820 X-tractor Gene) according to the manufacturer's recommendation. Faeces were tested for the molecular presence of ECoV as previously reported (Pusterla et al., 2013).

Statistical analyses

Data were summarised using descriptive statistics, with the median and range reported for non-parametric data. Numerical data for ECoV qPCR positive only horses were compared to the qPCR negative control cohort using a Mann–Whitney *U* test, with $P < 0.05$ considered significant. Holm's Sequential Bonferroni Procedure was applied to control for type I error associated with the testing of multiple hypotheses with clinicopathological data (Holm, 1979). Differences in season prevalence were analysed with a Fisher's exact test, with $P < 0.05$ considered significant.

Results

Fecal samples from 498 equine patients >1 year of age were tested for ECoV by qPCR over the specified time period. Thirty-three adult horses met the study criteria, including 12 mares, 20 geldings, and one stallion. Of these 33 horses, 30 were found to be positive for ECoV only, and 3 were diagnosed with ECoV and additional co-infections. Co-infections included one horse with *Salmonella* spp. infection (identified by fecal qPCR), one with *Actinobacillus equuli* peritonitis (identified by abdominal fluid culture), and one with both rhinitis B virus (identified by nasal swab qPCR) and *Salmonella* spp. (Group E; identified by fecal culture) infections. Horses were a median of 11 (range 2–37) years of age and of mixed breeds (Supplementary material). Thirty horses were hospitalised, and 3 were seen as outpatients or by the ambulatory service.

Horses positive for ECoV were presented for a combination of complaints elaborated in Table 1. Colic signs tended to be mild, with one horse presenting with net reflux following nasogastric intubation and two presenting with large colon impactions. Data on housing were lacking in 13/33 horses. Nineteen of the 20 horses (95%) for which information was available were housed at a multi-horse facility with horse traffic, and one horse (5%) was distinctly not from a high traffic environment. One horse was associated with a barn with five additional confirmed ECoV cases, two study horses were from the same barn and hospitalised within the same week, and three separate study horses were associated with horses with fevers at their respective farms. Five of 22 horses (23%) for which travel history was available had traveled to a horse show within the previous 3 weeks. Twenty-one of 33 (64%) cases occurred in colder months, with a significant difference between the number of cases seen between January and March and the other three seasons (Fig. 1; $P < 0.02$).

Thirty-three horses negative for ECoV on fecal qPCR were identified as controls, including 15 mares, 17 geldings, and one stallion. Horses were a median of 10 (1–30) years of age and of mixed breeds (Supplementary material). Presenting complaints are found in Table 1. Two of 21 horses (10%) for which travel history was available had recently been to a show. Housing information was available in 18 horses, of which 12/18 (67%) were housed at a

facility with an open herd. Final clinical diagnoses included fever of unknown origin ($n = 6/33$; 18%), colitis ($n = 5/33$; 15%), colic ($n = 2/33$; 6%), diarrhea ($n = 2/33$; 6%), colic and fever of unknown origin ($n = 2/33$; 6%), Anaplasmosis ($n = 2/33$; 6%), and large colon impaction ($n = 2/33$; 6%).

Initial examination and clinicopathological findings

Initial physical examination parameters and CBCs for ECoV-positive and negative horses are shown in Table 1. Seven of 30 horses (23%) with ECoV only and 9 horses negative for ECoV had loose manure/diarrhea. There were no significant differences in the number of horses with loose manure or lactate concentration >2 mmol/L between the ECoV-positive only and control groups. True thrombocytopenia was identified in four horses with ECoV, of which one horse had a degenerative left shift with bands and metamyelocytes, one had a regenerative left shift, and one had a leukocytosis of >15.0 cells $\times 10^9/L$. Horses positive for ECoV had significantly lower total WBC, neutrophil, and lymphocyte counts than negative controls ($P = 0.0006$, $P = 0.004$, $P = 0.007$, respectively). Serum amyloid A was evaluated in 3/30 horses positive for ECoV only and found elevated in 3/3 (100%), with a median concentration of 1080 (191–1833) $\mu\text{g/mL}$. All 4/33 control horses with serum amyloid A analysed had elevated concentrations, with a median of 1561 (77–2237) $\mu\text{g/mL}$.

Results of serum biochemistry profiles are found in Table 2. There were no significant differences between horses positive for ECoV only and negative controls. Abnormalities in horses with ECoV only and the controls included, respectively, electrolyte derangements ($n = 27/28$, 96%; $n = 27/30$, 90%), hyperbilirubinemia ($n = 23/28$, 82%; $n = 15/30$, 50%), hyperglycemia ($n = 23/28$, 82%; $n = 14/30$, 47%), hyperlipidemia ($n = 13/28$, 46%; $n = 12/30$, 40%), hypoproteinemia with hypoalbuminemia ($n = 8/28$, 29%; $n = 9/30$, 30%), increased muscle enzymes ($n = 8/28$; 29%; $n = 13/30$, 43%), and decreased blood urea nitrogen ($n = 4/28$, 14%; $n = 8/30$, 27%). Azotemia was present in 3/28 (11%) of horses with ECoV and 2/30 (7%) without ECoV. Hyperphosphatemia was associated with azotemia in two horses with ECoV. Blood ammonia concentrations performed in three horses with ECoV were within normal limits, with a median concentration of 22.1 (17.9–27.9) $\mu\text{mol/L}$ (reference range 3.57–42.1 $\mu\text{mol/L}$). The horse with the highest initial ammonia concentration (27.9 $\mu\text{mol/L}$) had decreased concentrations (10.7 $\mu\text{g/dL}$) when measured 2 days later. Bile acids were analysed in one horse with ECoV and were elevated. This horse also had elevated liver enzymes and initial triglyceride concentrations >6.78 mmol/L, but ammonia concentrations were not performed.

Additional diagnostics

Additional diagnostics at intake in horses positive for ECoV only included abdominal ultrasound ($n = 26/30$), rectal examination ($n = 16/30$), abdominocentesis ($n = 9/30$), nasogastric intubation ($n = 8/30$), and abdominal radiographs ($n = 5/30$). Ultrasound examination yielded no significant findings in 19/26 horses (73%) with ECoV. Small intestinal abnormalities included hypomotility ($n = 5/26$; 19%), increased wall thickness ($n = 4/26$; 15%), and hypermotility ($n = 2/26$; 8%); luminal distension was not apparent in any exam. Large intestinal abnormalities included increased wall thickness ($n = 4/26$; 15%), hypomotility ($n = 2/26$; 8%), luminal distension with fluid ($n = 2/26$; 8%) or gas ($n = 2/26$; 8%), and hypermotility ($n = 1/26$; 4%). Peritoneal effusion was present in 1 horse (1/26; 4%). Rectal examination indicated scant faeces ($n = 4/16$; 25%), mild colon impaction ($n = 3/16$; 19%), mild colonic gas distension ($n = 2/16$; 13%), taut bands ($n = 2/16$; 13%), soft manure ($n = 1/16$; 6%), an unrelated mass ($n = 1/16$; 6%), and no significant findings in 3 horses (3/16; 19%).

Table 1

Presenting complaints, median (range) physical examination parameters and initial complete blood counts in cohorts of horses positive for equine coronavirus (ECoV) infection and a co-infection, ECoV only, and negative controls, with statistical comparison between horses positive for ECoV only and negative controls.

| | RR | ECoV (n = 30) | ECoV + co-infection (n = 3) | Control (n = 33) | P-value |
|---|----------|--|--------------------------------------|---|---------|
| Presenting complaint | | | | | |
| Historic fever | | 25/30, 83% | 3/3, 100% | 18/33, 55% | |
| Anorexia | | 14/30, 47% | 2/3, 67% | – | |
| Colic | | 13/30, 43% | 2/3, 67% | 14/33, 42% | |
| Lethargy | | 8/30, 27% | – | 7/33, 21% | |
| Leukopenia | | 5/30, 17% | – | 1/33, 3% | |
| Diarrhea | | 1/30, 3% | – | 8/33, 24% | |
| Tachypnea | | 1/30, 3% | – | – | |
| Foot soreness | | 1/30, 3% | – | – | |
| Haemorrhagic rectal discharge | | – | – | 1/33, 3% | |
| Historic temperature (°C) | | (n = 25/30) 40 (38.3–41.6) | (n = 2/3) 39.8–40.3 | (n = 18/33) 39.3 (37.2–40.7) | |
| Physical examination | | (n = 29/30) | (n = 3/3) | (n = 32/33) | |
| Temperature (°C) | | 38.5 (37–39.9) | 37.7 (37.5–38) | 38 (36.9–40.6) | |
| Heart rate (beats/min) | | 48 (32–72) | 54 (32–72) | 48 (28–96) | |
| Resp. rate (breaths/min) | | 20 (12–60) | 32 (24–40) | 20 (10–88) | |
| Peripheral lactate (mmol/L) | <2 | (n = 21/30) 1.3 (0.7–14.5) 4 > RR | (n = 3/3) 1.4 (0.7–2.1) 1 > RR | (n = 19/33) 1.6 (0.8–13.4) 6 > RR | |
| CBC | | (n = 29/30) | (n = 3/3) | (n = 33/33) | |
| WBC (cells × 10 ⁹ /L) | 5.0–11.6 | 3.0 (0.68–16.2) 22 < RR, 3 > RR | 5.0 (1.42–5.18) 1 < RR | 5.68 (1.74–18.73) 22 < RR, 3 > RR | 0.0006 |
| Metamyelocytes (cells × 10 ⁹ /L) | 0 | 0.17 (0.21–3.25) 2 > RR | 0 | 0 | |
| Toxic bands (cells × 10 ⁹ /L) | Rare | 0.13 (0–7.96) 19 > RR | 0.70 (0.31–0.83) 3 > RR | 0 (0.10–2.77) 13 > RR | |
| Neutrophils (cells × 10 ⁹ /L) | 2.6–6.8 | 1.26 (0.15–14.4) 21 < RR, 2 > RR | 0.47 (0.23–1.90) 3 < RR | 3.96 (0.19–17.1) 12 < RR, 7 > RR | 0.004 |
| Lymphocytes (cells × 10 ⁹ /L) | 1.6–5.8 | 0.86 (0.42–3.47) (n = 30/30) 25 < RR | 1.6 (0.85–3.47) 1 < RR | 1.4 (0.23–5.0) 21 < RR | 0.007 |
| Platelet count (×10 ⁹ /L) | 100–225 | 122 (58–164) 4 < RR | 120 (117–137) | 147 (86–248) (n = 32/33) 2 < RR, 1 > RR | |
| Fibrinogen (mg/dL) | 100–400 | 400 (200–600) 1 > RR | 400 (300–500) 1 > RR | 300 (100–900) 5 > RR | |
| HCT (%) | 30–46 | 37.0 (24.4–66.7) (n = 30/30) 5 < RR 3 > RR | 40.3 (36.6–45.2) | 34.6 (20.8–53.4) 5 < RR, 3 > RR | |
| Total protein (g/dL) | 58–87 | 62 (52–77) (n = 30/30) 6 < RR | 62 (60–73) | 63 (35–82) 7 < RR | |
| Length of hospitalisation (days) | | (n = 27/30) 5 (0.5–14) | (n = 3/3) 7 | (n = 24/33) 3 (1–10) | |
| Survival to discharge | | 26/27 (96%) | 3/3 (100%) | 31/33 (94%) | |

CBC, complete blood count; HCT, haematocrit; HR, heart rate; RR, reference range; <RR or > RR, number of horses with values less than or greater than the reference range; Resp. rate, respiratory rate; WBC, white blood cell count.

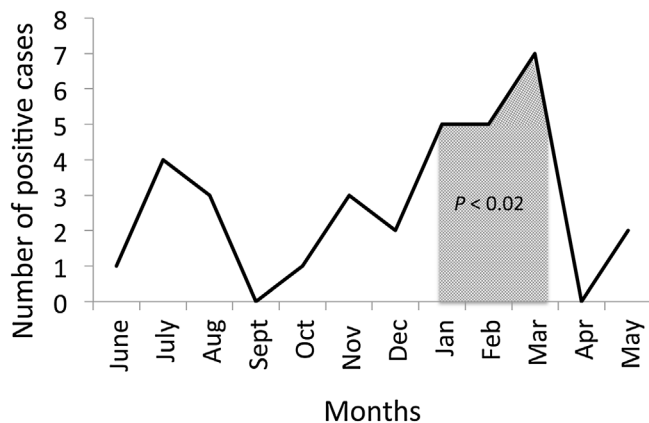


Fig. 1. Number of equine coronavirus positive cases over the months of the year from 1 March 2012 through 31 March 2018. January through March had significantly higher numbers of positive cases compared to other times of the year ($P < 0.05$).

Abdominal ultrasound was performed in 23/33 control horses, and findings were similar to those described in the ECoV-positive group (Supplemental material). Four of 23 controls also received thoracic ultrasound exams, with pulmonary changes in 3/4. There were no significant differences in the number of horses with small intestinal or large intestinal abnormalities between the ECoV only and negative control groups. Rectal examinations were performed in 19/33 control horses. Abnormalities included gas-distended ($n = 3/19$; 16%), fluid-filled ($n = 2/19$; 11%) or impacted large colon ($n = 2/19$; 11%); loose faeces ($n = 2/19$; 11%), loose ($n = 1/19$; 5%) or dry ($n = 1/19$; 5%) faeces and gas-distended colon, hard faeces ($n = 1/19$; 5%), and faeces with frank blood and rectal mucosal edema ($n = 1/19$; 5%). There were no significant findings on rectal exam in 6/19 (32%).

Abdominocentesis findings for horses positive for only ECoV indicated a median lactate concentration of 1.5 (1–2.3) mmol/L, total protein of 22 (6–29) g/L, and total nucleated cell count of 1.52 (0.42–4.6) cells × 10⁹/L. Horses negative for ECoV had a median lactate concentration of 2 (0.2–13.9) mmol/L, total protein 15

Table 2
Serum biochemistry profiles in 28 horses with equine coronavirus (ECoV) only, three horses with ECoV and a co-infection, and 30 negative control horses, with median (range) presented. Statistically significant differences were not demonstrated between the group with ECoV only and negative controls ($P > 0.05$).

| | RR | ECoV (n = 28/30) | ECoV + co-infection (n = 3/3) | Control (n = 30/33) |
|-----------------------------------|-------------|-----------------------|-------------------------------|-----------------------|
| iMagnesium (mmol/L) | 0.47–0.70 | 0.35 (0.29–0.56) | 0.33 (0.25–0.41) | 0.4 (0.24–0.61) |
| Sodium (mmol/L) | 125–137 | 132 (117–136) | 129 (129–132) | 134 (122–139) |
| Potassium (mmol/L) | 3.0–5.6 | 3.0 (1.6–4.4) | 3.4 (3.0–3.4) | 3.2 (2.7–4.8) |
| Chloride (mmol/L) | 91–104 | 96 (77–101) | 94 (89–101) | 97 (77–103) |
| Phosphorus (mmol/L) | 0.68–1.52 | 0.68 (0.23–3.94) | 0.68 (0.48–1.39) | 0.74 (0.48–4.68) |
| Calcium (mmol/L) | 2.85–3.53 | 2.7 (2.4–2.95) | 2.7 (2.68–2.85) | 2.7 (1.83–3.28) |
| Anion Gap (mmol/L) | 9–17 | 14 (11–46) | 16 (13–18) | 14 (11–31) |
| Bicarbonate (mmol/L) | 23–32 | 25 (11–28) | 25 (15–28) | 25 (19–30) |
| Blood urea nitrogen (mmol/L) | 4.28–9.64 | 5.36 (2.86–11.78) | 12 (9–14) | 5.36 (3.21–25.7) |
| Creatinine (μ mol/L) | 79.56–176.8 | 114.92 (79.56–327.08) | 1 (1–1.3) | 114.92 (61.88–318.24) |
| Glucose (mmol/L) | 2.78–5.94 | 7.27 (5.38–10.38) | 6.16 (5.99–8.32) | 6.22 (2.83–9.82) |
| Total protein (g/L) | 58–77 | 61 (46–74) | 57 (55–73) | 60 (42–76) |
| Albumin (g/L) | 27–42 | 30 (19–36) | 31 (25–36) | 30 (22–37) |
| Globulin (g/L) | 16–50 | 29 (22–38) | 30 (26–37) | 31 (21–52) |
| AST (IU/L) | 168–494 | 270 (186–1881) | 299 (293–372) | 259 (146–6980) |
| Creatine kinase (IU/L) | 119–287 | 239 (86–813) | 484 (125–596) | 211 (79–30,451) |
| ALP (IU/L) | 86–285 | 157 (91–655) | 459 (98–550) | 130 (22–316) |
| GGT (IU/L) | 8–22 | 12 (8–85) | 18 (10–22) | 12 (7–83) |
| SDH (IU/L) | 0–8 | 3 (0–173) | 0 (0–6) | 3 (0–47) |
| Triglycerides (mmol/L) | 0.02–0.46 | 0.49 (0.24–8.12) | 2.19 (2.01–4.61) | 0.59 (0.17–3.3) |
| Total bilirubin (μ mol/L) | 8.55–39.33 | 44.46 (18.81–188.1) | 46.17 (42.75–141.93) | 37.62 (10.26–141.93) |
| Direct bilirubin (μ mol/L) | 3.42–10.26 | 3.42 (1.71–15.39) | 3.42 (1.71–3.42) | 3.42 (1.71–8.55) |
| Indirect bilirubin (μ mol/L) | 5.13–29.07 | 42.75 (15.39–172.71) | 42.75 (39.33–140.22) | 34.2 (6.84–138.51) |

ALP, Alkaline phosphatase; AST, Aspartate aminotransferase; GGT, Gamma-glutamyltransferase; RR, reference range; SDH, Sorbitol dehydrogenase.

(5–38)g/L, and total nucleated cell count 1.15 (0.47–13.1) cells $\times 10^9$ /L when measured in 12/33, 11/33, and 14/33 horses, respectively (Supplementary material). There were no significant differences in lactate, protein, or nucleated cell count between horses positive for ECoV and controls.

Nasogastric intubation performed in those positive for ECoV only yielded net reflux in 1/7 horses (14%), with 7 L recovered. A nasogastric tube was passed in 17/33 (52%) of the control horses, with 11 L of net reflux in one horse. Abdominal radiographs showed mild to moderate sand accumulation in 2/5 horses (40%) with ECoV only, fluid lines in 2/5 (40%), and no significant findings in 1/5 (20%). Radiographs were performed in 12/33 control horses and indicated scant to moderate sand accumulation in 5/12 (42%).

Among the ECoV-positive horses, 30/33 horses were tested for at least one additional pathogen (including gastrointestinal, respiratory, or blood-borne agents), with 3/30 (10%) diagnosed with known co-infections (salmonellosis, *Actinobacillus sp.* peritonitis, and salmonellosis with concurrent Rhinitis B virus). Diagnostics to assess for the direct presence of other infectious agents in horses positive for ECoV and controls are found in Table 3. A complete list of diagnostic tests performed can be found in the Appendix: Supplementary Material.

Table 3

Additional diagnostic testing to assess for the direct presence of other infectious agents performed in horses positive for equine coronavirus (ECoV) compared to negative controls.

| | ECoV n = 33 | Control n = 33 |
|---|------------------------|-------------------------------------|
| Salmonella culture | 30 (91%) (1 positive) | 25 (76%) (all negative) |
| Respiratory qPCR panel | 11 (33%) (1 positive) | 8 (24%) (all negative) |
| <i>A. phagocytophilum</i> PCR and/or buffy coat smear | 6 (18%) (all negative) | 6 (18%) (2 positive) |
| <i>C. difficile</i> ELISA | 0 | 3 (9%) (all negative) |
| Abdominal fluid culture | 1 (3%) (positive) | 2 (6%) (all negative) |
| Blood culture | 1 (3%) (negative) | 1 (3%) (negative) |
| <i>C. pseudotuberculosis</i> PCR | 0 | 1 (abdominal fluid) (3%) (negative) |

Therapy and hospitalisation

Medical therapy instituted was available in 28/30 (93%) horses positive for ECoV only and 33/33 negative horses (see Appendix: Supplementary Material). Follow-up complete blood counts (CBC) were performed in 21/30 (70%) horses positive for ECoV only and 13/33 (39%) negative horses and are shown in Table 4. The last CBC was performed a median of 4 (2–14) and 3 (2–9) days after the intake CBC for horses positive and negative for ECoV, respectively. Follow-up fecal qPCRs were performed in 15/33 (45%) of all horses positive for ECoV. Seven of the 15 (47%) horses retested remained ECoV qPCR positive when tested a median of 3 (2–8) days after the initial qPCR. Eight of the 15 (53%) horses retested had negative ECoV qPCR results when tested a median of 7 (5–16) days after the initial qPCR.

Length of hospitalisation and survival rate for horses with and without ECoV are shown in Table 1. One horse with ECoV died 12 h after admission and had a 6-day history of fever, diarrhea, and leukopenia, a peripheral lactate of 14.5 mmol/L, haematocrit of 66.7%, degenerative left shift with metamyelocytes, and evidence of multi-organ dysfunction syndrome and disseminated intravascular coagulation. Necropsy revealed necrohaemorrhagic colitis and enteritis with disseminated vascular thrombi, congestion and petechiation of the heart and other organs, and renal infarcts. Immunohistochemistry identified ECoV within the contents of the colon. Thirty-two of 33 control horses were managed medically while one required colic surgery. Two control horses did not survive, with diagnoses at necropsy of (1) colitis and megasophagus and (2) toxic shock syndrome secondary to *S. aureus* infection. There was no significant difference in survival to discharge between horses with ECoV and the control population.

Horses positive for ECoV and co-infections

Diagnostic findings for horses positive for ECoV and a co-infection were similar to horses positive for ECoV only and included small intestinal hypomotility and colonic fluid on ultrasound ($n = 1/3$), scant ($n = 2/3$) or malodorous ($n = 1/3$) faeces on rectal examination, and sand on radiographs ($n = 1/3$). The horse

Table 4

Median (range) follow-up and admission complete blood cell counts in horses positive for equine coronavirus (ECoV) only by quantitative polymerase chain reaction and 13 control horses. Follow-ups occurred a median of 4 days (range, 2–14 days) and 3 days (range, 2–9 days) after hospital intake for ECoV-positive and control horses, respectively.

| | RR | n >RR | n <RR | ECoV follow-up (n = 21/30) | ECoV admission (n = 29/30) | Control follow-up (n = 13/33) | Control admission (n = 33/33) |
|---|------------|---------|---------|-------------------------------|-------------------------------|----------------------------------|----------------------------------|
| WBC (cells × 10 ⁹ /L) | 5.0 – 11.6 | 1 (5%) | 5 (24%) | 6.40 (2.9–13.3) | 3.0 (0.68–16.2) | 6.32 (4.6–9.7) | 5.68 (1.74–18.73) |
| Toxic bands (cells × 10 ⁹ /L) | rare | 6 (29%) | 0 | 0 (0–8.57) | 0.13 (0–7.96) | 0 (1.26–3.96) | 0 (0.10–2.77) |
| Metamyelocytes (cells × 10 ⁹ /L) | 0 | 0 | 0 | 0 | 0.17 (0.21–3.25) | 0 | 0 |
| Neutrophils (cells × 10 ⁹ /L) | 2.6–6.8 | 2 (10%) | 4 (19%) | 3.19 (0.66 – 11.74) | 1.26 (0.15–14.4) | 3.50 (1.3–7.7) | 3.96 (0.19–17.1) |
| Lymphocytes (cells × 10 ⁹ /L) | 1.6–5.8 | 0 | 8 (38%) | 1.80 (1.20– 4.15) | 0.86 (0.42–3.47) | 2.00 (1.2–5.9) | 1.4 (0.23–5.0) |
| Total protein (g/L) | 58–87 | 0 | 3 (14%) | 65 (50–72) | 62 (52–77) | 61 (54–68) | 63 (35–82) |
| HCT (%) | 30–46 | 0 | 2 (10%) | 36.7 (26.8 – 44) | 37.0 (24.4–66.7) | 34.3 (31.9–41.4) | 34.6 (20.8–53.4) |
| Platelets (× 10 ⁹ /L) | 100– 225 | 0 | 1 (5%) | 145 (99– 224) | 122 (58–164) | 147 (112–183) | 147 (86–248) |
| Fibrinogen (mg/dL) | 100–400 | 1 (5%) | 0 | 400 (300–500) | 400 (200–600) | 300 (300–500) | 400 (300–500) |

HCT, haematocrit; RR, reference range; WBC, white blood cell count.

co-infected with *Actinobacillus spp.* peritonitis had 5 L of net reflux upon initial nasogastric intubation and had markedly abnormal abdominocentesis results (lactate 17 mmol/L, total protein 61 g/L, total nucleated cell count 165 cells × 10⁹/L). Follow-up CBCs were similar to the rest of the ECoV-positive cohort, except for the horse with *Actinobacillus* peritonitis with persistent thrombocytopenia, hyperproteinemia, and hyperfibrinogenemia.

Discussion

This study showcases common presentations and the range of disease severity in horses positive for ECoV. It is the first study to document advanced diagnostic findings and outcomes for a cohort of hospitalised horses positive for ECoV and provides a comparison to a matched group of horses negative for ECoV. A recent seroprevalence study showed an increased proportion of ECoV infection in draft horses (17.6%), which was not apparent in the current study and likely reflects a difference in populations (Kooijman et al., 2017). Similar to other studies, ECoV infection rates were increased in the cooler months of the year, with peak prevalences in January through March likely related to husbandry changes and possible decreased viability of the virus in hot, dry temperatures (Kooijman et al., 2017; Pusterla et al., 2018).

The clinical presentations and clinicopathological findings in the ECoV-positive group were similar to those observed in horses after experimental inoculation with ECoV (Nemoto et al., 2014). Additionally, the diarrhea qPCR panel and salmonella fecal culture performed are considered sensitive screening tools for other infectious gastrointestinal pathogens. Thus, with the exception of the co-morbidities found, disease presentations observed in our equine patients are considered likely associated with ECoV infection. However, horses can shed ECoV subclinically and intermittently, and causation between clinical signs and fecal qPCR positivity for ECoV cannot be claimed. Furthermore, diagnostics performed were based on clinical findings and case progression and were often incomplete in ruling out additional pathogens (e.g. 11/33 positive for ECoV had respiratory qPCR panels performed). There is the potential for co-infections to have been underrepresented and their contribution to clinical signs unaccounted for. The likelihood of false negative results in horses tested for multiple pathogens through qPCR is considered relatively low unless the pathogen is shed intermittently, as qPCR is known to have high sensitivity and specificity for identifying and quantifying genetic material if present. If anything, the likelihood of identifying pathogens that might be present but not toxigenic may be a risk if qPCR is the sole test utilised (e.g. *C. difficile* toxin gene positive on qPCR but not elaborating toxin).

Horses positive for ECoV had similar presentations, diagnostics, and management to many of the horses negative for ECoV. This result is not surprising since submitting fecal samples for qPCR on

horses that present with fever, colic, or loose manure is one of the first steps performed at the hospital as part of the diagnostic plan and for infectious disease control. Horses positive for ECoV had significantly lower WBC, neutrophil, and lymphocyte counts than the negative controls, suggesting a more florid acute inflammatory response in those with ECoV. The majority of the biochemistry abnormalities in both the ECoV-positive and ECoV-negative groups can be explained by inappetence leading to decreased electrolyte intake and possible electrolyte secretion into the gastrointestinal lumen. Metabolic derangements (e.g. hyperlipidemia) were also common and attributed to a negative energy balance, as well as systemic inflammation (Barsnick et al., 2014). Ammonia concentrations were not evaluated in most of the ECoV cases and would have been interesting to document, as hyperammonemia is a reported complication of ECoV associated with higher mortality (Fielding et al., 2015). The three horses that were evaluated for ammonia had concentrations within laboratory references. However, a horse positive for ECoV only with the highest ammonia concentration at 27.9 μmol/L showed a decrease to 10.7 μmol/L when measured 2 days later, possibly indicating a relative hyperammonemia. The fatality rate for all horses with ECoV was low at 3%, which is less than the reported 7% in one outbreak and 27% in another (Pusterla et al., 2013; Fielding et al., 2015). Thus, prognosis can be considered good with appropriate supportive care even in more severe cases of ECoV, although owners should be warned about the possibility of complications and death, comparable to that seen in horses presenting for fever, lethargy or colic for other reasons.

This case series is the first known documentation of co-infections in adult horses positive for ECoV. Co-infections between ECoV and other gastrointestinal pathogens have been reported in diarrheic foals but were not reported in previous studies documenting outbreaks of ECoV (Slovic et al., 2014; Fielding et al., 2015; Pusterla et al., 2018). The reasons for co-infection with ECoV remain unknown. The authors speculate that ECoV allows for reduced colonisation resistance of the gastrointestinal microbiome or reduced immune function, permitting colonisation with pathogenic organisms like salmonellae, or allowing *Actinobacillus equuli* to translocate across the gut wall. As mentioned earlier, diagnostic testing to evaluate for the presence of co-infecting pathogens was not complete in many cases in this study, and further research is required prior to drawing conclusions about the impact ECoV and co-infections have on treatment and prognosis in adult horses.

Approximately 50% of horses positive for ECoV in the current study were still shedding the organism when retested ≤8 days after admission. This is similar to studies where horses inoculated with infected faeces shed for >9 days, independent of clinical signs, or ranged in shedding from 5 to 9 days (Nemoto et al., 2014; Schaefer et al., 2018). At the current hospital, clinicians tend to

retest faeces via fecal qPCR every 5–10 days to determine when the horse is no longer shedding. Horses positive for ECoV were hospitalised 2 days longer than ECoV-negative horses, which may reflect increased disease severity or the decision to hospitalise the horse until it was no longer infectious.

This study is limited by its retrospective nature. As mentioned, the clinical signs and progression seen in the ECoV-positive cohort were identical to those observed after experimental inoculation, however a claim for causation cannot be made. The presence of viremia and/or seroconversion in addition to clinical signs and positive fecal qPCRs would provide stronger evidence that ECoV was responsible for the disease presentations seen (Nemoto et al., 2014; Kooijman et al., 2016). There is currently no gold standard ante-mortem test for diagnosing ECoV, and qPCR appears to be the most sensitive diagnostic for detecting ECoV in faeces (Nemoto et al., 2015). However, false negative fecal qPCR results remain possible if single samples are submitted early in the course of disease (fecal shedding can start 24 h after horses become febrile), and as intermittent shedding can occur (Nemoto et al., 2014; Schaefer et al., 2018). In a clinic setting, many horses screened for gastrointestinal pathogens through fecal qPCR have tests performed at an isolated time point rather than serially due to cost purposes, including the control horses used in this study. There is the potential for control horses in the current study to have been misclassified as ECoV-negative when they were in fact positive, which may have impacted some of the statistical results.

An additional limitation is that diagnostics and treatments were based on clinician preferences, which may have biased the dataset. As horses were often presented on emergency, there was sometimes a lag between admission and blood work submission, with time for treatment to alter clinicopathological parameters. This limitation applied to both ECoV-positive and control populations and was unlikely to influence the comparison between the two groups.

Conclusions

ECoV infection should be considered a differential diagnosis for adult horses that present with fever, colic, and anorexia. Marked leukopenia was more severe in ECoV-positive horses compared to horses with similar clinical signs but that are ECoV-negative. Coinfections should be evaluated for as they can occur but may be uncommon and have unknown or varying significance. The disease has a low mortality rate, but horses may require intensive supportive care to resolve systemic inflammation, metabolic and electrolyte disturbances, and possibly prevent bacteremia from gastrointestinal translocation.

Conflict of interest statement

None of the authors have any financial or personal relationships that could inappropriately influence or bias the content of the manuscript.

Acknowledgement

The house officers who participated in equine patient care are acknowledged for their contributions to the study.

Appendix A. Supplementary data

Supplementary material related to this article can be found, in the online version, at doi:<https://doi.org/10.1016/j.tvjl.2019.05.001>.

References

- Barnsick, R.J., Hurcombe, S.D., Dembek, K., Frazer, M.L., Slovis, N.M., Saville, W.J., Toribio, R.E., 2014. Somatotrophic axis resistance and ghrelin in critically ill foals. *Equine Veterinary Journal* 46, 45–49.
- Fielding, C.L., Higgins, J.K., Higgins, J.C., McIntosh, S., Scott, E., Giannitti, F., Mete, A., Pusterla, N., 2015. Disease associated with equine coronavirus infection and high case fatality rate. *Journal of Veterinary Internal Medicine* 29, 307–310.
- Holm, S., 1979. A simple sequentially rejective multiple test procedure. *Scandinavian Journal of Statistics* 2, 65–70.
- Kooijman, L.F., Mapes, S., Pusterla, N., 2016. Development of an equine coronavirus-specific enzyme-linked immunosorbent assay to determine serologic responses in naturally infected horses. *Journal of Veterinary Diagnostic Investigation* 28, 414–418.
- Kooijman, L.J., James, K., Mapes, S.M., Theelen, M.J., Pusterla, N., 2017. Seroprevalence and risk factors for infection with equine coronavirus in healthy horses in the USA. *The Veterinary Journal* 220, 91–94.
- Miszczak, F., Tesson, V., Kin, N., Dina, J., Balasuriya, U.B., Pronost, S., Vabret, A., 2014. First detection of equine coronavirus (ECoV) in Europe. *Veterinary Microbiology* 171, 206–209.
- Nemoto, M., Oue, Y., Morita, Y., Kanno, T., Kinoshita, Y., Niwa, H., Ueno, T., Katayama, Y., Bannai, H., Tsujimura, K., et al., 2014. Experimental inoculation of equine coronavirus into Japanese draft horses. *Archives of Virology* 159, 3329–3334.
- Nemoto, M., Morita, Y., Niwa, H., Bannai, H., Tsujimura, K., Yamanaka, T., Kondo, T., 2015. Rapid detection of equine coronavirus by reverse transcription loop-mediated isothermal amplification. *Journal of Virological Methods* 215–216, 13–26.
- Oue, Y., Morita, Y., Kondo, T., Nemoto, M., 2013. Epidemic of equine coronavirus at Obihiro Racecourse, Hokkaido, Japan in 2012. *Journal of Veterinary Internal Medicine* 75, 1261–1265.
- Pusterla, N., Mapes, S., Wademan, C., White, B.A., Sapp, K., Burns, P., Ormond, C., Butterworth, K., Bartol, J., Magdesian, K.G., 2013. Emerging outbreaks associated with equine coronavirus in adult horses. *Veterinary Microbiology* 162, 228–231.
- Pusterla, N., Vin, R., Leutenegger, C.M., Mittel, L.D., Divers, T.J., 2018. Enteric coronavirus infection in adult horses. *The Veterinary Journal* 231, 13–18.
- Schaefer, E., Harms, C., Viner, M., Barnum, S., Pusterla, N., 2018. Investigation of an experimental infection model of equine coronavirus in adult horses. *Journal of Veterinary Internal Medicine* 32, 2099–2104.
- Slovis, N.M., Elam, J., Estrada, M., Leutenegger, C.M., 2014. Infectious agents associated with diarrhea in neonatal foals in central Kentucky: a comprehensive molecular study. *Equine Veterinary Journal* 46, 311–316.