




Feline coronavirus-associated myocarditis in a domestic longhair cat

Maria A Ernandes¹, Anna M Cantoni²,
Federico Armando² , Attilio Corradi²,
Lorenzo Ressel³ and Alice Tamborini⁴

Journal of Feline Medicine and Surgery Open Reports
1–5

© The Author(s) 2019

Article reuse guidelines:

sagepub.com/journals-permissions

DOI: 10.1177/2055116919879256

journals.sagepub.com/home/jfmsopenreports

This paper was handled and processed by the European Editorial Office (ISFM) for publication in *JFMS Open Reports*



Abstract

Case summary A 9-month-old entire male domestic longhair indoor cat presented with a 3-week history of fluctuating fever, weight loss and small intestine diarrhoea, which was unresponsive to antibiotics and supportive treatment. Abdominal ultrasound revealed severe jejunal and ileocolic junction intestinal wall thickening with loss of layering. An enterectomy was performed and histopathology revealed severe pyogranulomatous enteritis with vasculitits, compatible with the diagnosis of feline infectious peritonitis (FIP). Four days after surgery, the cat re-presented with anorexia and acute onset of expiratory dyspnoea. Echocardiography showed left ventricular hypertrophy and bilateral atrial enlargement. Congestive heart failure caused by hypertrophic cardiomyopathy was suspected and treatment with furosemide was started, which led to amelioration of the clinical signs. The following day, four-limb ataxia, hypermetria and bilateral uveitis were evident. Given the persistent anorexia and worsening of the clinical signs, the cat was humanely euthanized and a post-mortem examination was performed. Necropsy revealed multifocal pyogranulomatous lesions involving multiple organs (adrenal glands, kidneys, lungs, brain, myocardium, lymph nodes, liver), compatible with the diagnosis of FIP. Immunohistochemistry performed on the myocardium revealed feline coronavirus-positive macrophages associated with pyogranulomatous lesions, justifying a diagnosis of feline coronavirus-associated myocarditis.

Relevance and novel information To the authors' knowledge, the case described here represents the first published report of feline coronavirus-associated myocarditis. This should be considered as a possible differential diagnosis in cats presenting with cardiac-related signs and other clinical signs compatible with FIP.

Keywords: Feline infectious peritonitis; myocarditis; heart failure; post mortem

Accepted: 9 September 2019

Case description

A 9-month-old entire male domestic longhair indoor cat presented to the referring veterinarian (Ambulatorio Veterinario Brollo, Italy) with 1-week history of small intestinal diarrhoea. The cat was recently dewormed with milbemycin oxime/praziquantel (Milbemax tablets for small cats and kittens; Elanco); it was not vaccinated and had no travel history outside the country. On physical examination, all vital parameters were within normal limits, except for raised rectal temperature (39.6°C). On abdominal palpation, there was a suspicion of thickened intestines. Upon serology, the patient was negative for

¹Ambulatorio Veterinario Brollo, Fidenza (Parma), Italy

²General Pathology and Veterinary Pathological Anatomy Unit, Department of Veterinary Science, University of Parma, Parma, Italy

³Department of Veterinary Pathology and Public Health, Institute of Veterinary Science, University of Liverpool, Neston, UK

⁴Department of Internal Medicine, Dick White Referrals, Six Mile Bottom, UK

Corresponding author:

Alice Tamborini DVM, MRVCS, DipECVIM-CA (Internal Medicine), RCVS and European Specialist in Veterinary Internal Medicine – Companion Animals, Department of Internal Medicine, Dick White Referrals, Station Farm, London Road, Six Mile Bottom CB8 0UH, UK
Email: alice.tamborini@yahoo.com



feline leukaemia virus (FeLV) p27 antigen and feline immunodeficiency virus (FIV) antibodies (IDEXX Laboratories). Faecal flotation did not detect any ova, parasites or cysts. ELISA antigens for *Giardia* species and parvovirus (IDEXX Laboratories) were not retrieved from the faeces. Infectious causes of diarrhoea, such as viruses (coronavirus, parvovirus, rotavirus, etc), bacteria (primary or secondary infections) or, less likely, parasites, were considered most likely, while other causes (ie, dietary intolerance, pancreatitis, intussusception, etc), although less likely, were not completely ruled out. There was neither a history of toxin exposure nor dietary indiscretion. The patient was started on antibiotic treatment: metronidazole/spiramycin (Stomorgyl two tablets [Merial]; metronidazole 12.5mg/kg and spiramycin 75,000UI/kg q24h PO for 14 days), along with supportive treatment of the diarrhoea with prebiotics, probiotics (Florentero tablets [Candioli]; Carobin Pet paste [NBF Lanes]; both given as needed) and a highly digestible diet (i/d Hill's Prescription Diet).

Two days later, the patient re-presented to the referring veterinarian with persistent diarrhoea and weight loss (100g). On physical examination, all vital parameters were within normal limits, except for rectal temperature, which was still slightly raised (39.7°C). The cat was normally hydrated. Haematology and biochemistry revealed moderate non-regenerative anaemia (20.3%; reference interval [RI] 24–45%) and hyperglobulinaemia (5.4g/dl; RI 2.8–5.1) with an albumin/globulin ratio of 0.44. The anaemia was likely due to chronic disease or gastrointestinal blood loss, whereas the hyperglobulinaemia and low A/G ratio were most likely explained by an inflammatory or infectious process. Given that the patient was cardiovascularly stable, the treatment course was extended further.

As the diarrhoea was still present 18 days after the first presentation, the patient was referred to another veterinarian (MAE), in order to further investigate the nature of the clinical signs. An abdominal ultrasound demonstrated severe jejunal wall thickening (up to 9mm) with loss of layering, while no other abnormalities were observed. An exploratory laparotomy was performed under general anaesthesia, in order to collect full-thickness biopsies. This revealed markedly thickened jejunal loops and ileocolic junction (the latter showed partial lumen occlusion) and mild ileocaecal lymphadenomegaly. An enterectomy and a termino-terminal surgical anastomosis between the proximal ileum and the descending colon were performed. Furthermore, one of the ileocaecocolic lymph nodes was excised. Two days after surgery, the patient was discharged, awaiting the results.

Histopathology of the jejunal biopsies revealed several aggregates of macrophages and neutrophils, together with smaller numbers of lymphocytes and plasma cells transmurally infiltrating the intestinal wall with a multifocal vasculocentric pattern. Histopathology

of the ileocaecocolic lymph node showed reactive hyperplasia. A morphological diagnosis of pyogranulomatous enteritis and vasculitis compatible with feline infectious peritonitis (FIP) was made; however, owing to financial restraints and an unfavourable prognosis, immunohistochemistry (IHC) was not performed at this stage.

Four days after surgery, the cat re-presented with anorexia and acute onset of respiratory distress. Upon physical examination, tachypnoea (60 breaths/min) with mild expiratory effort and slightly pale mucous membranes were evident. On thoracic auscultation, a few crackles were audible bilaterally. The cat was hospitalised, placed in an oxygen cage and administered intravenous furosemide (Diuren 1% 10mg/ml solution for injections [Teknofarma]: 1mg/kg q6h initially, then 1mg/kg q12h). After 12h, a considerable amelioration of the clinical signs was seen.

By the following day, the respiratory rate and pattern normalised and therefore furosemide was administered subcutaneously at a dose of 1mg/kg q12h. Owing to the suspicion of cardiac-related dyspnoea, an echocardiography was performed and revealed left ventricular hypertrophy and bilateral atrial enlargement. Congestive heart failure (CHF) owing to hypertrophic cardiomyopathy (HCM) was considered most likely. Nevertheless, the cat started developing four-limb ataxia and weakness. A complete neurological examination was therefore carried out, which revealed ataxia and hypermetric gait on all four limbs and a mild decreased menace reflex bilaterally. Based on the findings, a cerebellar lesion was suspected. An ophthalmic evaluation revealed bilateral uveitis with anterior chamber opacity (worse on the left eye); on examination of the fundus, retinal blood vessel oedema was evident.

Owing to the worsening of the clinical signs and unfavourable long-term prognosis, the cat was humanely euthanized and a post-mortem examination was performed. The latter showed: an ileoileal termino-terminal surgical anastomosis; markedly enlarged mesenteric lymph nodes and spleen; diffusely enlarged and pale kidneys with multifocal variably sized firm white nodules protruding from the cortex; well circumscribed, firm white left lung lobe nodules of about 1mm diameter with pleural thickening; a small amount of serohaemorrhagic pleural and pericardial fluid; and thickened myocardium with minimal mitral valve endocardiosis.

Formalin-fixed paraffin-embedded 5µm sections were prepared on polylysine-coated slides for routine histological staining (haematoxylin and eosin) and for IHC. For the demonstration of coronavirus in tissue, a mouse anti-coronavirus antibody (clone FCV3-70) was used as described previously.¹ FIP lesions that tested positive for feline coronavirus (FCoV) antigen served as positive controls. For negative controls, consecutive sections were stained with an isotype-matched mouse non-specific

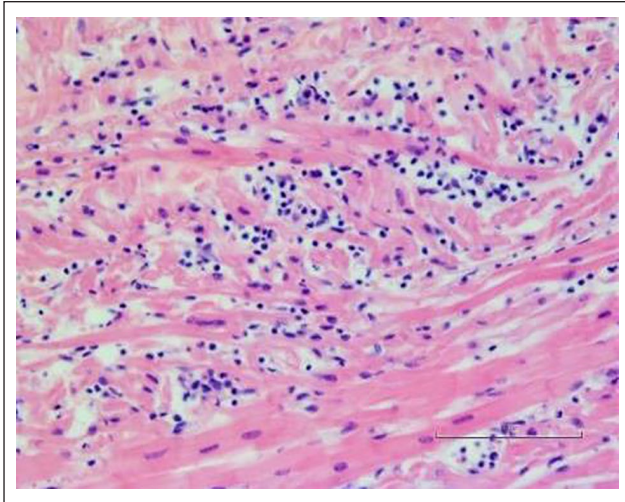


Figure 1 Histopathology of the heart. Myocardocytes are mildly multifocally swollen and degenerated. The interstitium between myocardocytes is diffusely expanded by oedema and focal infiltration by inflammatory aggregates characterised by a high number of lymphocytes, plasma cells and fewer macrophages. Haematoxylin eosin ($\times 200$)

antibody following the same protocol.¹ Histopathology revealed pyogranulomatous infiltration involving several organs: adrenal glands, kidneys, lungs, brain, myocardium, lymph nodes and liver. In particular, the myocardium fibres were markedly expanded by oedema and by multifocal inflammatory infiltrates of lymphocytes, plasma cells and macrophages (Figure 1). There was no evidence of the typical HCM histological findings, such as myofibre disarray, extensive interstitial fibrosis or focal endocardial thickening. The findings were compatible with a diagnosis of FIP. IHC was performed on the myocardium (Figure 2) and revealed several FCoV-positive cells morphologically consistent with macrophages. A post-mortem diagnosis of FCoV-associated myocarditis was finally made.

Discussion

FCoV is found worldwide and is over-represented in multi-cat households; it replicates in enterocytes. FCoV infection is usually asymptomatic; however, it can cause transient mild or occasionally severe acute or chronic vomiting and/or diarrhoea with weight loss that is unresponsive to supportive treatment.²⁻⁴ If the cat's macrophages fail to eliminate the virus, it replicates within their cytoplasm and FIP develops.^{2,3} FIP is a fatal, immune-mediated disease and is a common infectious cause of death in cats.^{2,3,5,6} The non-effusive form is characterised by the development of granulomatous lesions within the kidneys, central nervous system, eyes and parenchymatous organs (including the intestine, where ileocolic junction masses are common).^{3,7,8} The hallmark of the effusive form is the vasculitis-induced fluid

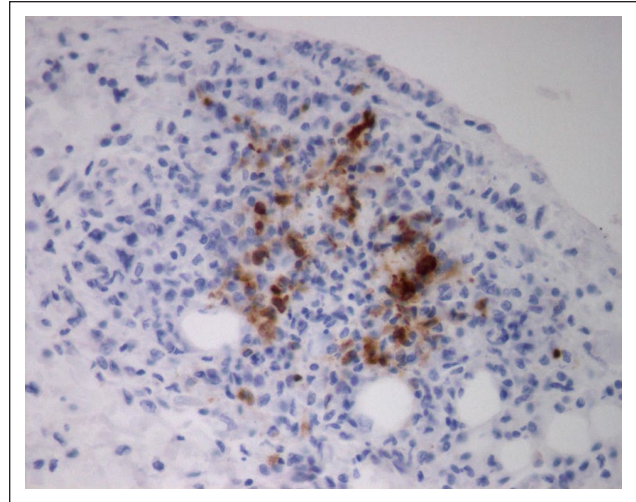


Figure 2 Immunohistochemistry of the myocardium. In an area close to the left atrioventricular valve, feline coronavirus (FCoV)-positive macrophages are evident (brown stain) in association with neutrophils and macrophages. Indirect immunoperoxidase ($\times 400$)

accumulation in body cavities (pleural, peritoneal and pericardial).^{3,9,10} The clinical presentation described in our case report was compatible with what reported in literature. However, the onset of CHF was unexpected and initially considered unrelated to FIP. It is worth mentioning that, in cats with FIP, some unusual manifestations have been described, such as a mediastinal cyst-like mass in the thorax, skin fragility syndrome and other skin lesions, orchitis or priapism, while no FCoV-associated myocarditis has been described yet.¹¹⁻¹⁶

A definitive diagnosis of FIP is often challenging. A score system based on history, clinical signs, laboratory abnormalities and level of antibody titres has been suggested in order to assess the likelihood of FIP.^{2,3} However, necropsy with histology and IHC are still considered the gold standards for the diagnosis of FIP.^{2,3,17-20} In the present case, necropsy revealed pyogranulomatous infiltration of multiple organs, including the myocardium. Furthermore, the multifocal vasculocentric pattern of the intestinal wall lesions would favour a monocyte-triggered spreading of the coronavirus to other organs (including the myocardium), as previously reported.¹ IHC performed on the myocardial tissue confirmed the presence of FCoV-positive macrophages. Given the absence of morphological signs consistent with HCM, the thickening of the myocardium was explained by the presence of oedema and inflammatory infiltrates composed of lymphocytes, plasma cells and FCoV-positive macrophages; therefore, a post-mortem diagnosis of FCoV-induced myocarditis, leading to the unusual representing picture (CHF), was made. To the authors' knowledge, this has never been reported before in the veterinary literature.

Myocarditis is a form of myocardial disease characterised by the presence of inflammation in response to physical, chemical and infectious agents. Reports of dogs and cats with infectious myocarditis caused by systemic diseases, such as protozoa (*Trypanosoma cruzi*, *Hepatozoon* species, *Leishmania* species, *Neospora caninum*, *Toxoplasma gondii*), viruses (FIV, parvovirus, West Nile virus), bacteria (*Bartonella* species, *Bacillus piliiformis*, *Citrobacter koseri*), spirochetes (*Borrelia burgdorferi*) and, in some cases, opportunistic fungi (*Blastomyces* species)^{21–34} have been described. To date, as far as the authors are aware, there have been no reports of FCoV as the cause of myocarditis. Therefore, this cat represents the first published report that viruses other than parvovirus and FIV can cause myocarditis in cats. Furthermore, our conclusion is that FCoV-associated myocarditis led to the onset of CHF and to the unusual clinical manifestation.

Conclusions

FCoV-associated myocarditis should be considered as a rare but possible differential diagnosis in cats presenting with cardiac-related signs and other clinical signs compatible with FIP. Histological examination, together with IHC, is needed to confirm the diagnosis, as previously reported. Studies on a large cohort of cats are needed to establish the prevalence of myocarditis in cats diagnosed with FIP.

Conflict of interest The authors declared no potential conflicts of interest with respect to the research, authorship, and/or publication of this article.

Funding The authors received no financial support for the research, authorship, and/or publication of this article.

Ethical approval This work involved the use of non-experimental animals only (owned and unowned), and followed internationally recognized high standards ('best practice') of individual veterinary clinical patient care. Ethical approval from a committee was not necessarily required.

Informed consent Informed consent (either verbal or written) was obtained from the owner or legal custodian of all animal(s) described in this work for the procedures undertaken. For any animals or humans individually identifiable within this publication, informed consent for their use in the publication (verbal or written) was obtained from the people involved.

ORCID iD Federico Armando  <https://orcid.org/0000-0002-2578-4409>

References

1 Kipar A, May H, Menger S, et al. **Morphologic features and development of granulomatous vasculitis in feline infectious peritonitis.** *Vet Pathol* 2005; 42: 321–330.

- 2 Tasker S. **Diagnosis of feline infectious peritonitis: update on evidence supporting available tests.** *J Feline Med Surg* 2018; 20: 228–243.
- 3 Hartmann K. **Feline coronavirus and feline infectious peritonitis.** In: Ettinger ST, Feldman EC and Côté E (eds). *Textbook of veterinary internal medicine.* 8th ed. St Louis, MO: Elsevier, 2017, pp 983–989.
- 4 Sabshin SJ, Levy JK, Tupler T, et al. **Enteropathogens identified in cats entering a Florida animal shelter with normal feces or diarrhea.** *J Am Vet Med Assoc* 2012; 241: 331–337.
- 5 Cave TA, Thompson H, Reid SW, et al. **Kitten mortality in the United Kingdom: a retrospective analysis of 274 histopathological examinations (1986 to 2000).** *Vet Rec* 2002; 151: 497–501.
- 6 Rohrbach BW, Legendre AM, Baldwin CA, et al. **Epidemiology of feline infectious peritonitis among cats examined at veterinary medical teaching hospitals.** *J Am Vet Med Assoc* 2001; 218: 1111–1115.
- 7 Harvey CJ, Lopez JW and Hendrick MJ. **An uncommon intestinal manifestation of feline infectious peritonitis: 26 cases (1986–1993).** *J Am Vet Med Assoc* 1996; 209: 1117–1120.
- 8 Kipar A, Koehler K, Bellmann S, et al. **Feline infectious peritonitis presenting as a tumour in the abdominal cavity.** *Vet Rec* 1999; 144: 118–122.
- 9 Fischer Y, Wess G and Hartmann K. **Pericardial effusion in a cat with feline infectious peritonitis.** *Schweiz Arch Tierheilkd* 2012; 154: 27–31.
- 10 Oliveira LB, Susta L, Rech R, et al. **Pathology in practice. Effusive FIP with fibrinous epicarditis in a cat.** *J Am Vet Med Assoc* 2014; 245: 899–901.
- 11 Vigani A, Giordano A and Travetti O. **Uncommon mediastinal cyst-like manifestation of feline infectious peritonitis.** *Vet Rec* 2009; 165: 239–241.
- 12 Trotman TK, Mauldin E, Hoffmann V, et al. **Skin fragility syndrome in a cat with feline infectious peritonitis and hepatic lipidosis.** *Vet Dermatol* 2007; 18: 365–369.
- 13 Cannon MJ, Silkstone MA and Kipar AM. **Cutaneous lesions associated with coronavirus-induced vasculitis in a cat with feline infectious peritonitis and concurrent feline immunodeficiency virus infection.** *J Feline Med Surg* 2005; 7: 233–236.
- 14 Bauer BS, Kerr ME, Sandmeyer LS, et al. **Positive immunostaining for feline infectious peritonitis (FIP) in a Sphinx cat with cutaneous lesions and bilateral panuveitis.** *Vet Ophthalmol* 2013; 16 Suppl 1: 160–163.
- 15 Sigurdardottir OG, Kolbjornsen O and Lutz H. **Orchitis in a cat associated with coronavirus infection.** *J Comp Pathol* 2001; 124: 219–222.
- 16 Rota A, Paltrinieri S, Jussich S, et al. **Priapism in a castrated cat associated with feline infectious peritonitis.** *J Feline Med Surg* 2008; 10: 181–184.
- 17 Addie DD, Paltrinieri S, Pedersen NC, et al. **Recommendations from workshops of the second international feline coronavirus/feline infectious peritonitis symposium.** *J Feline Med Surg* 2004; 6: 125–130.
- 18 Giori L, Giordano A, Giudice C, et al. **Performances of different diagnostic tests for feline infectious peritonitis in challenging clinical cases.** *J Small Anim Pract* 2011; 52: 152–157.

- 19 Hartmann K, Binder C, Hirschberger J, et al. **Comparison of different tests to diagnose feline infectious peritonitis.** *J Vet Intern Med* 2003; 17: 781–790.
- 20 Kipar A, Bellmann S, Kremendahl J, et al. **Cellular composition, coronavirus antigen expression and production of specific antibodies in lesions in feline infectious peritonitis.** *Vet Immunol Immunopathol* 1998; 65: 243–257.
- 21 Cannon AB, Luff JA, Brault AC, et al. **Acute encephalitis, polyarthritis, and myocarditis associated with West Nile virus infection in a dog.** *J Vet Intern Med* 2006; 20: 1219–1223.
- 22 Cassidy JP, Callanan JJ, McCarthy G, et al. **Myocarditis in sibling Boxer puppies associated with *Citrobacter koseri* infection.** *Vet Pathol* 2002; 39: 393–395.
- 23 Donovan TA, Balakrishnan N, Carvalho Barbosa I, et al. ***Bartonella* spp. as a possible cause or cofactor of feline endomyocarditis-left ventricular endocardial fibrosis complex.** *J Comp Pathol* 2018; 162: 29–42.
- 24 Joseph JL, Oxford EM and Santilli RA. **Transient myocardial thickening in a *Bartonella henselae*-positive cat.** *J Vet Cardiol* 2018; 20: 198–203.
- 25 Kegler K, Nufer U, Alic A, et al. **Fatal infection with emerging apicomplexan parasite *Hepatozoon silvestris* in a domestic cat.** *Parasit Vectors* 2018; 11: 428. DOI: 10.1186/s13071-018-2992-4.
- 26 Levy S and Duray P. **Complete heart block in a dog seropositive for *Borrelia burgdorferi*: similarity to human Lyme carditis.** *J Vet Intern Med* 1988; 2: 138–144.
- 27 Lichtensteiger CA, Heinz-Taheny K, Osborne TS, et al. **West Nile virus encephalitis and myocarditis in wolf and dog.** *Emerg Infect Dis* 2003; 9: 1303–1306.
- 28 Maxie MG and Robinson WF. **Cardiovascular system.** In: Jubb, Kennedy and Palmer's pathology of domestic animals. 5th ed. Vol. 3. Philadelphia, PA: Elsevier Saunders, 2007, pp 1–2.
- 29 Odin M and Dubey JP. **Sudden death associated with *Neospora caninum* myocarditis in a dog.** *J Am Vet Med Assoc* 1993; 203: 831–833.
- 30 Schmiedt C, Kellum H, Legendre AM, et al. **Cardiovascular involvement in 8 dogs with *Blastomyces dermatitidis* infection.** *J Vet Intern Med* 2006; 20: 1351–1354.
- 31 Torrent E, Leiva M, Segales J, et al. **Myocarditis and generalized vasculitis associated with leishmaniosis in a dog.** *J Small Anim Pract* 2005; 46: 549–552.
- 32 Varanat M, Broadhurst J, Linder KE, et al. **Identification of *Bartonella henselae* in 2 cats with pyogranulomatous myocarditis and diaphragmatic myositis.** *Vet Pathol* 2012; 49: 608–611.
- 33 Meurs KM, Fox PR, Magnon AL, et al. **Molecular screening by polymerase chain reaction detects panleukopenia virus DNA in formalin-fixed hearts from cats with idiopathic cardiomyopathy and myocarditis.** *Comp Pathol* 2000; 9: 119–126.
- 34 Rolim VM, Casagrande RA, Wouters AT, et al. **Myocarditis caused by feline immunodeficiency virus in five cats with hypertrophic cardiomyopathy.** *J Comp Pathol* 2016; 154: 3–8.